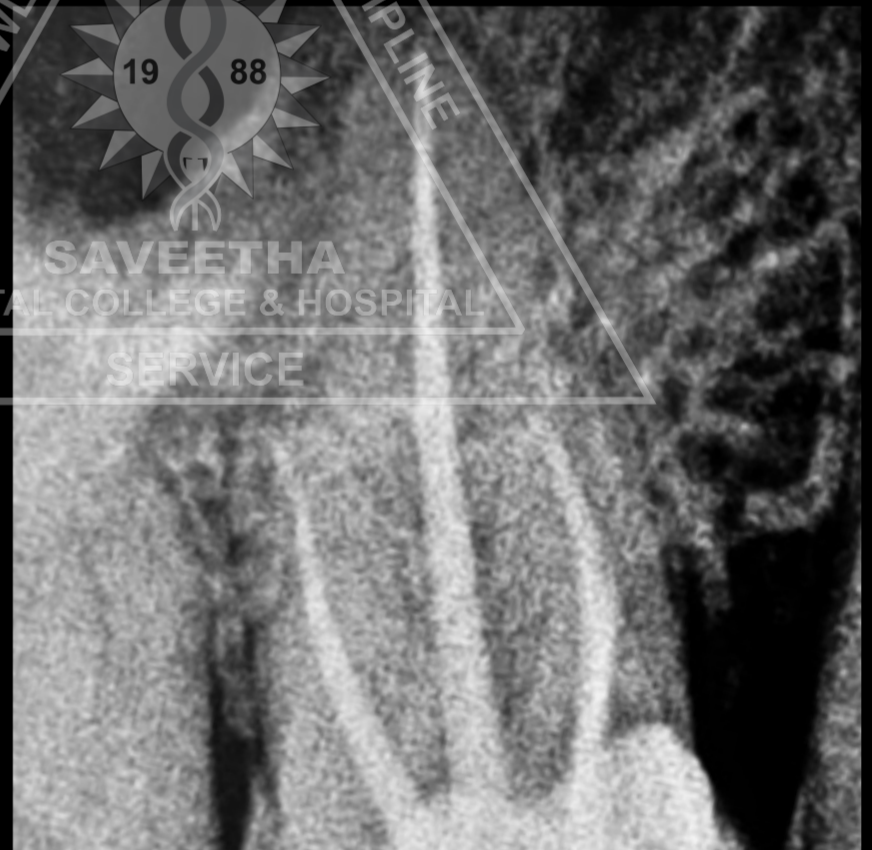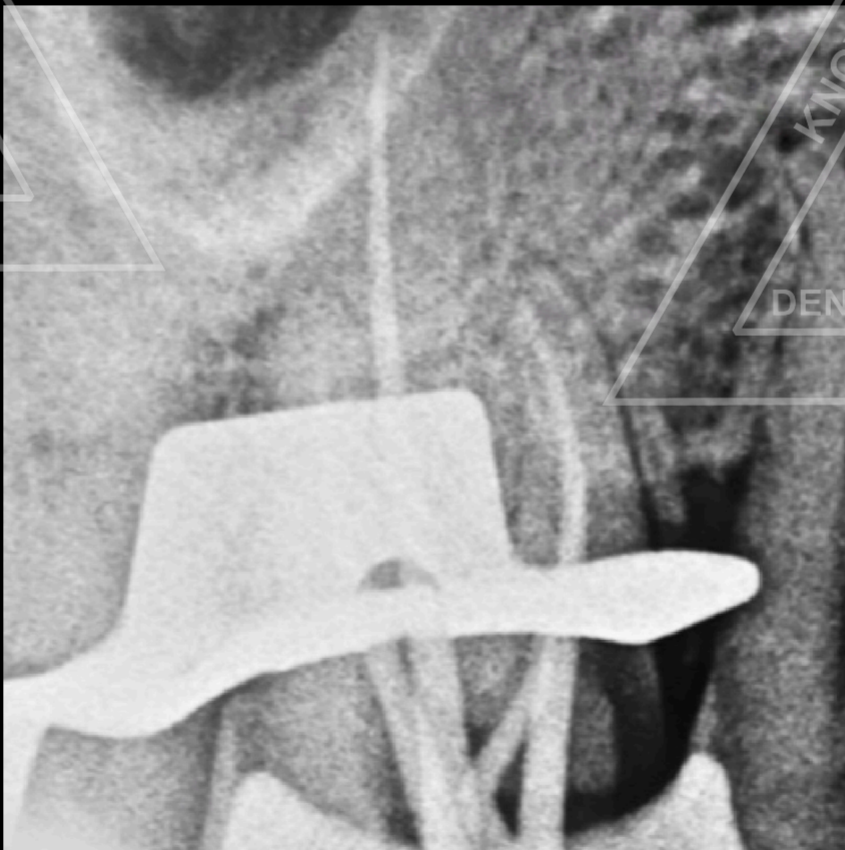
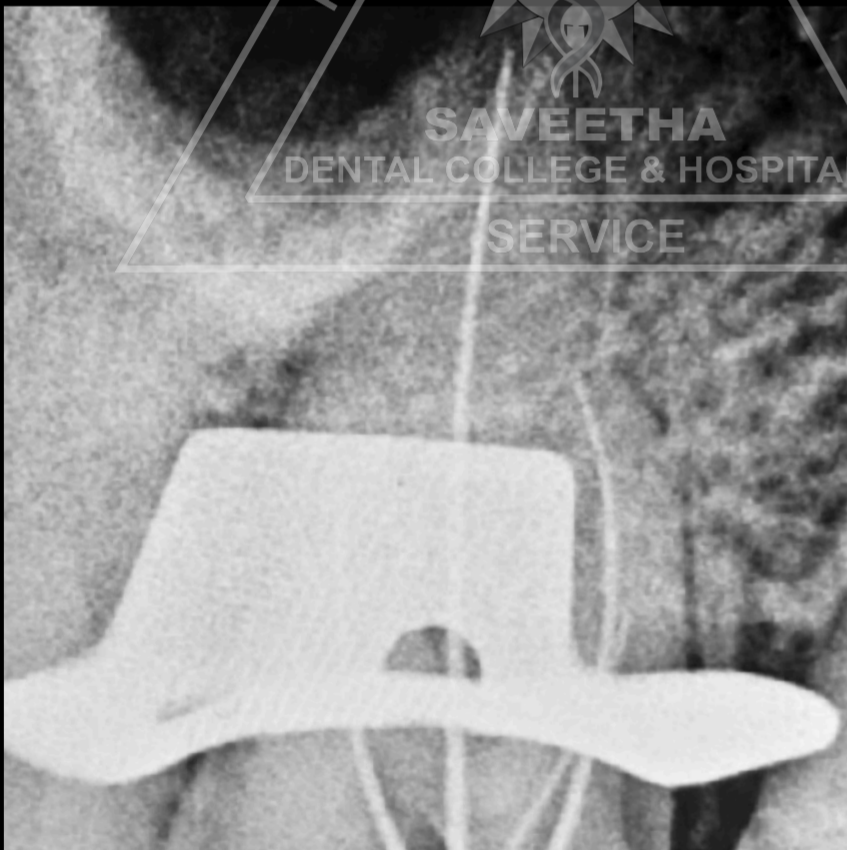
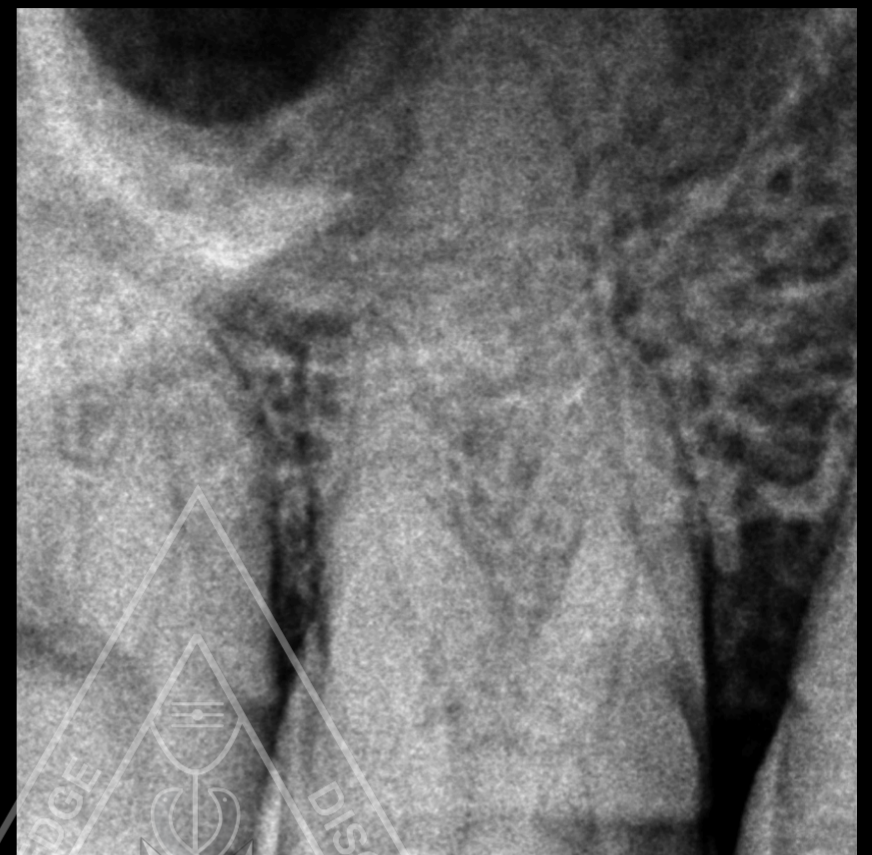
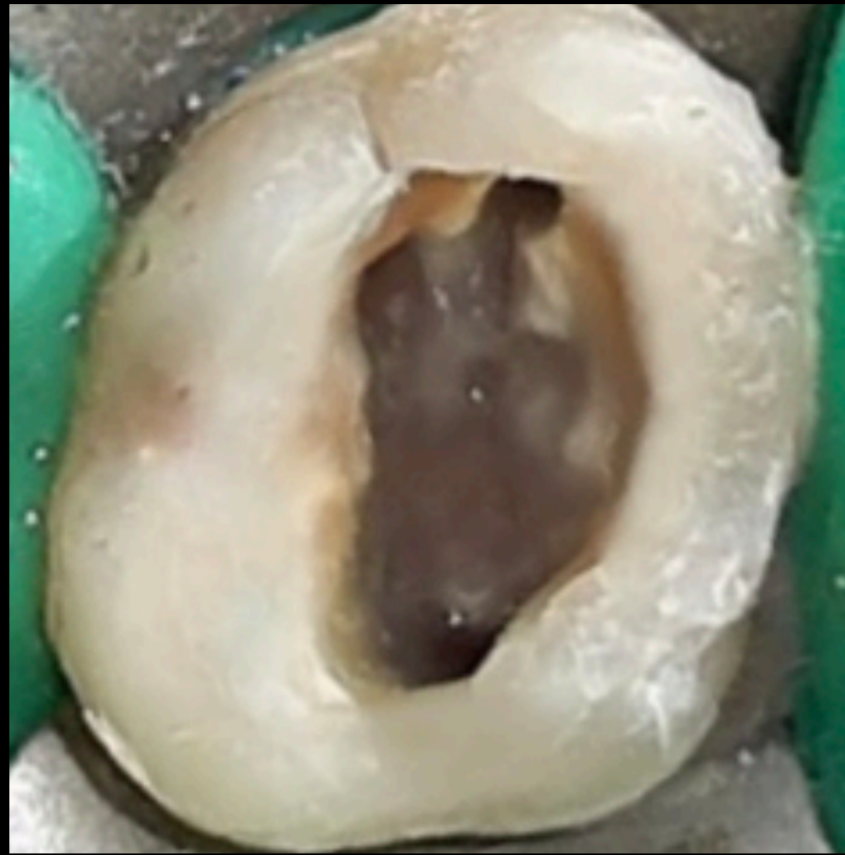

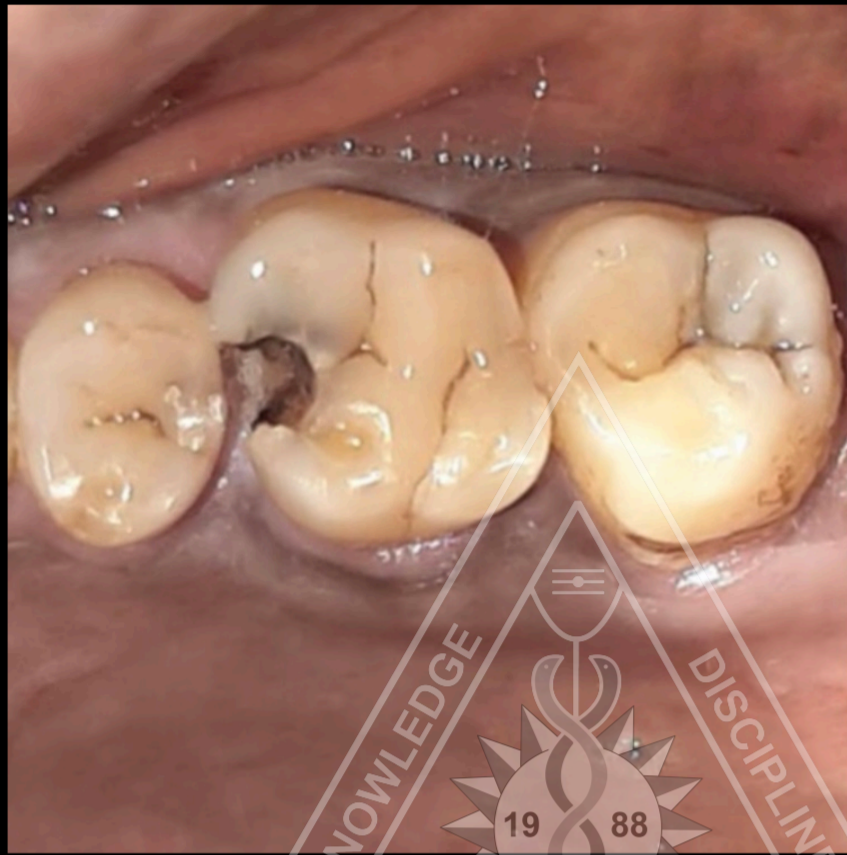
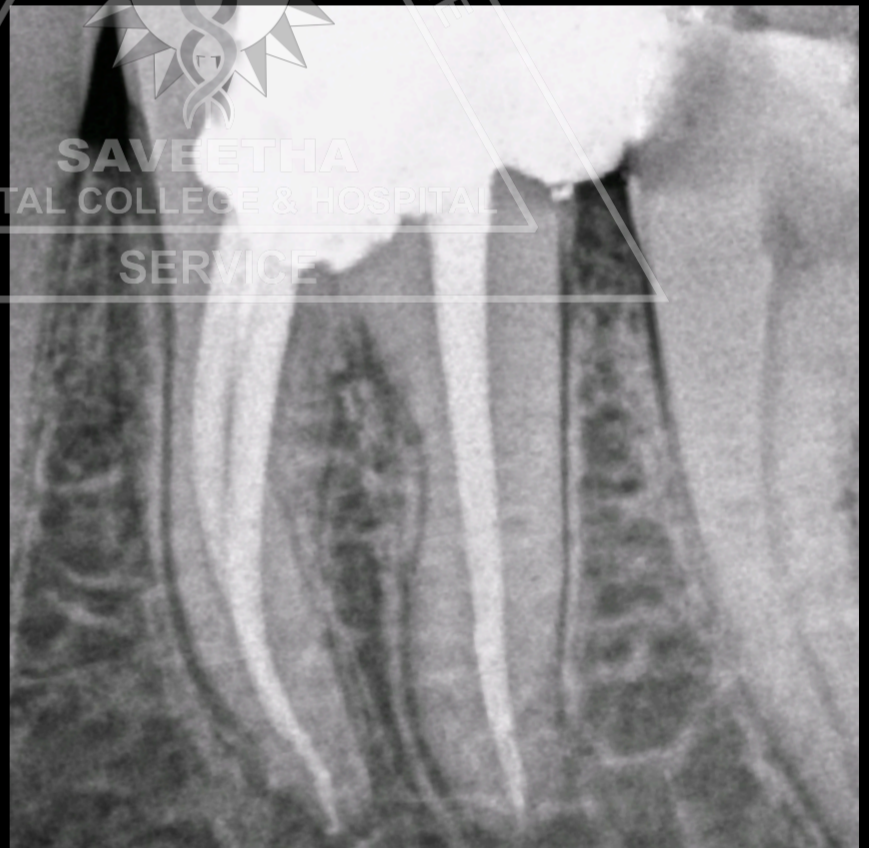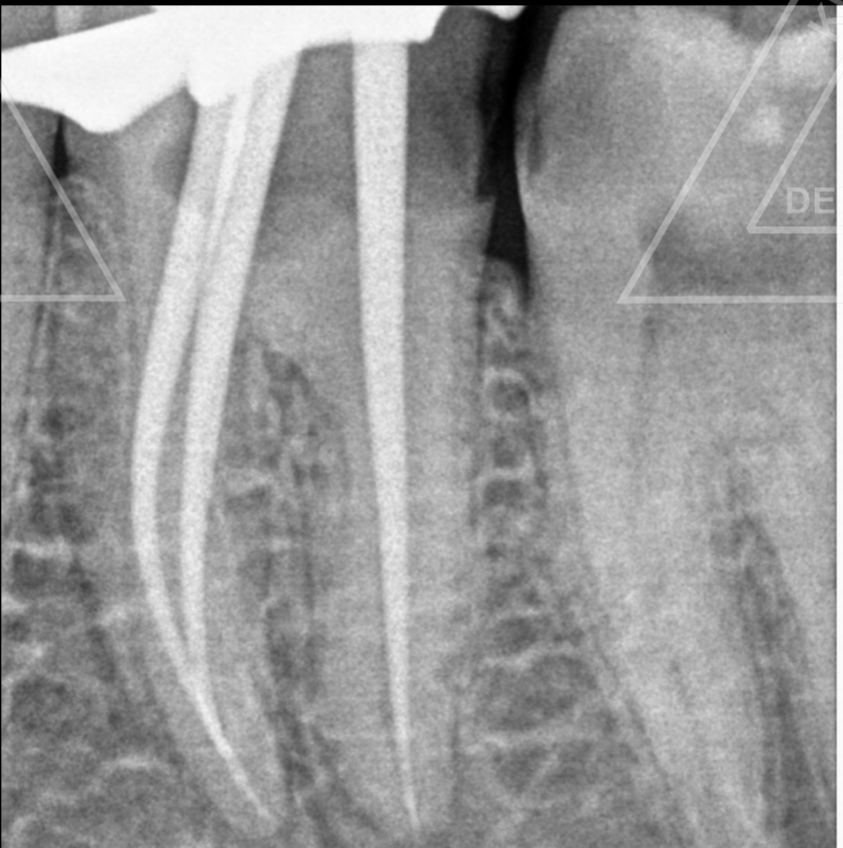
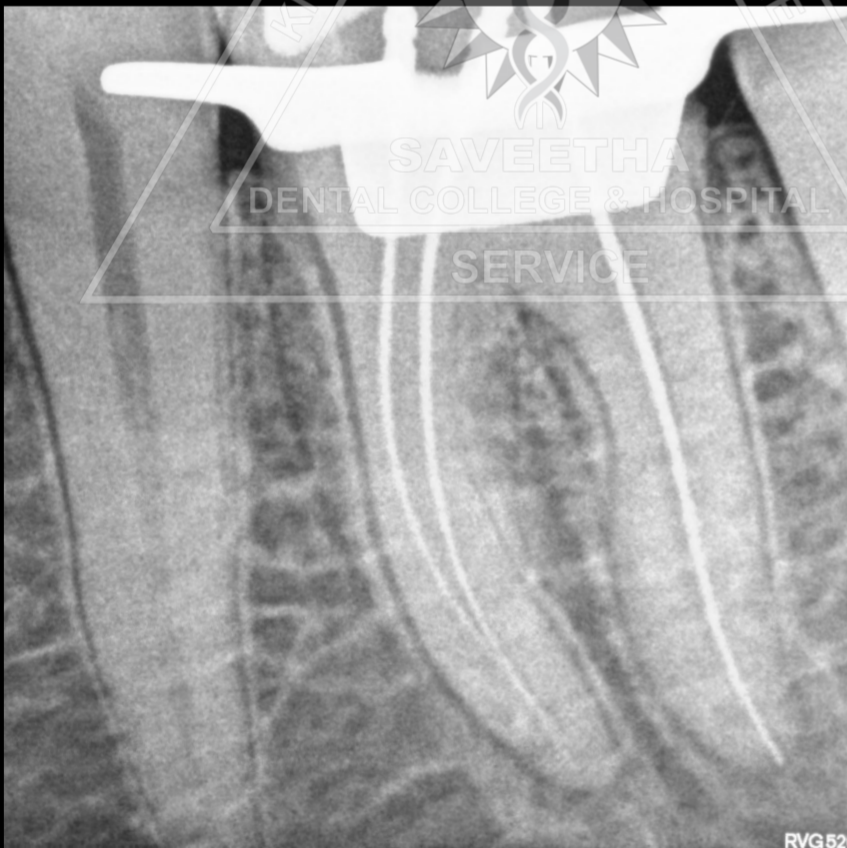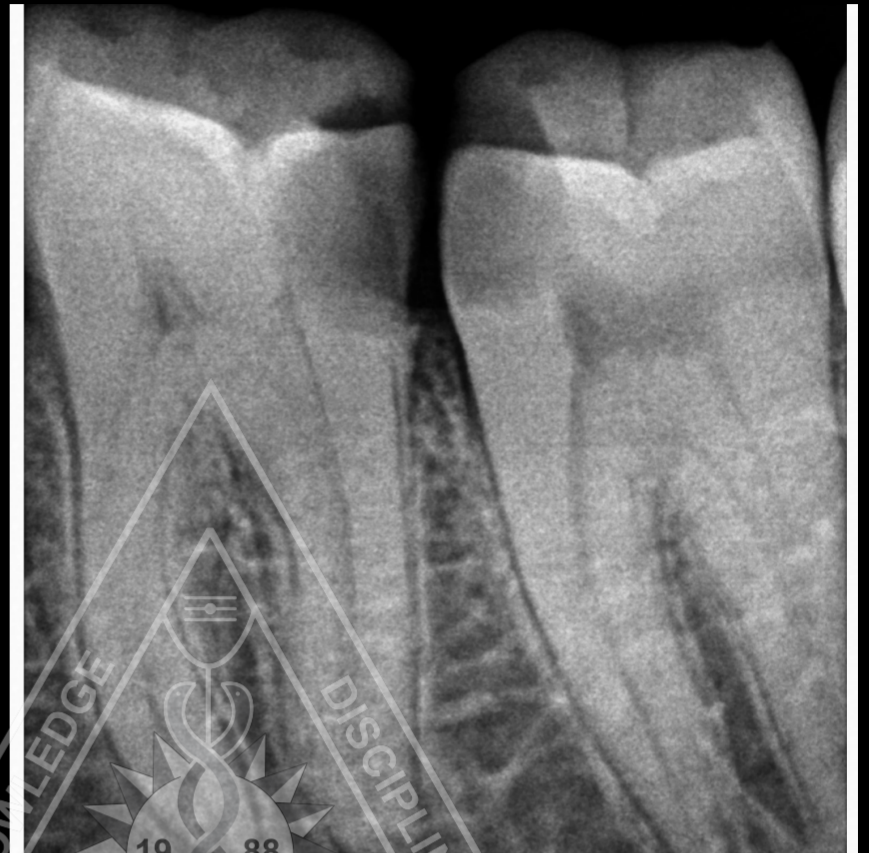
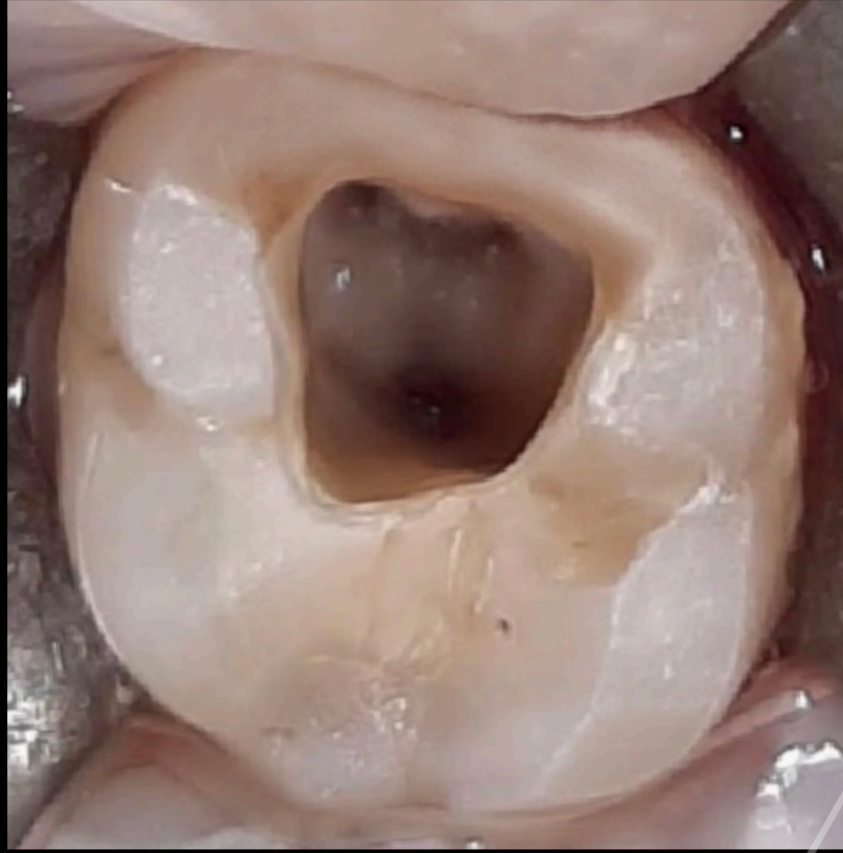
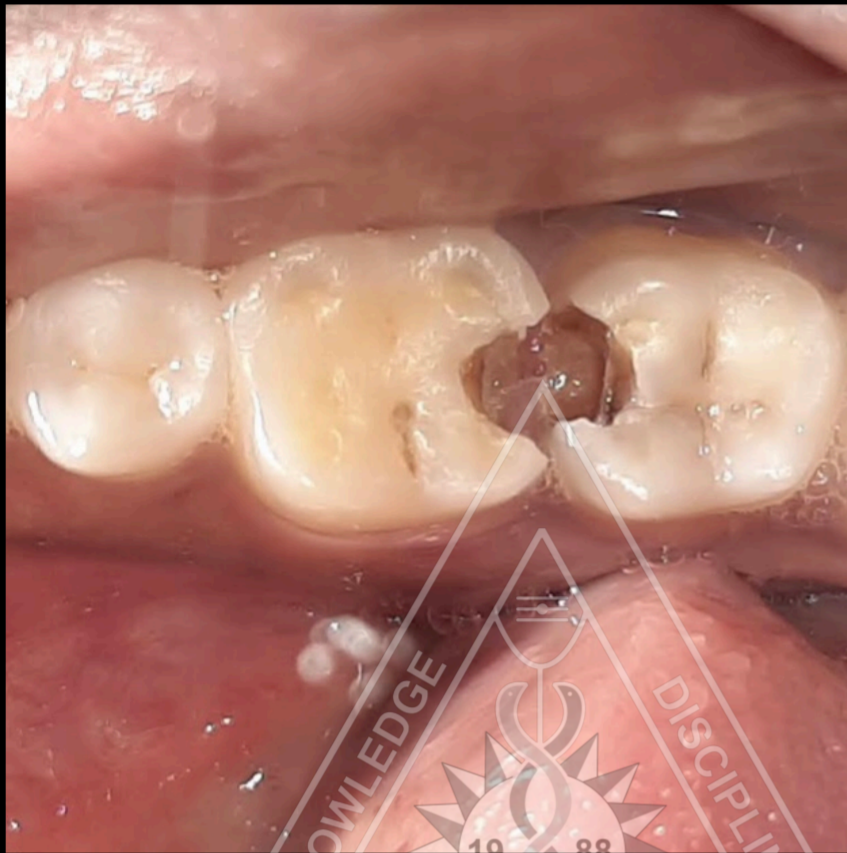# ROOT CANAL TREATMENT IN 16



**Dr Divya S B**

**I MDS ENDODONTICS**

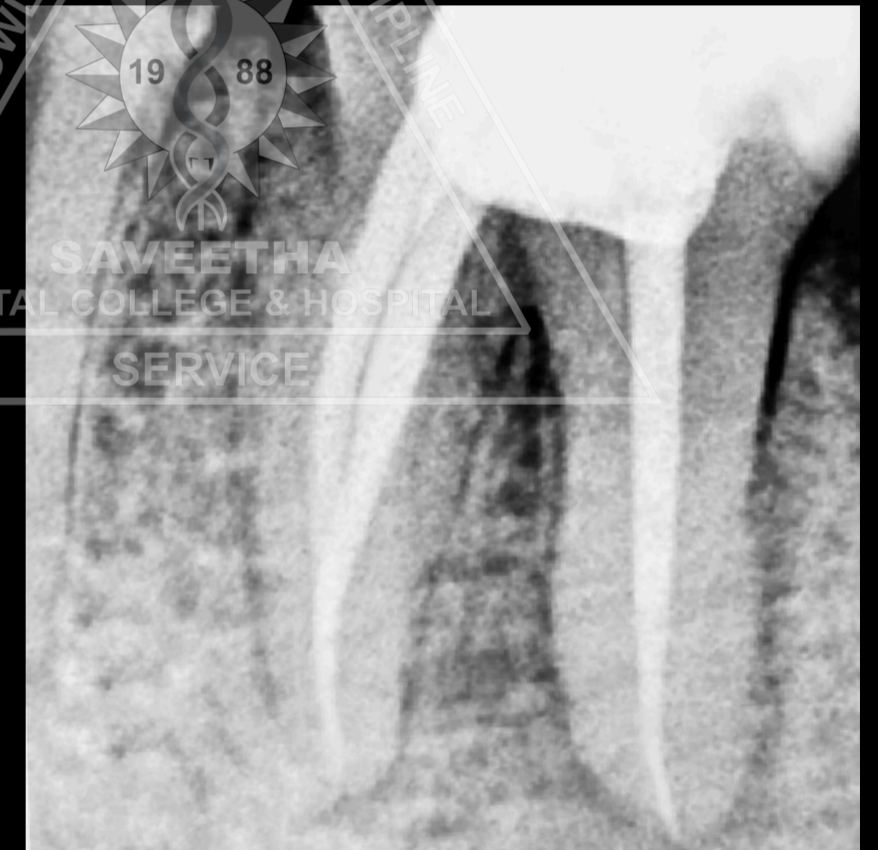
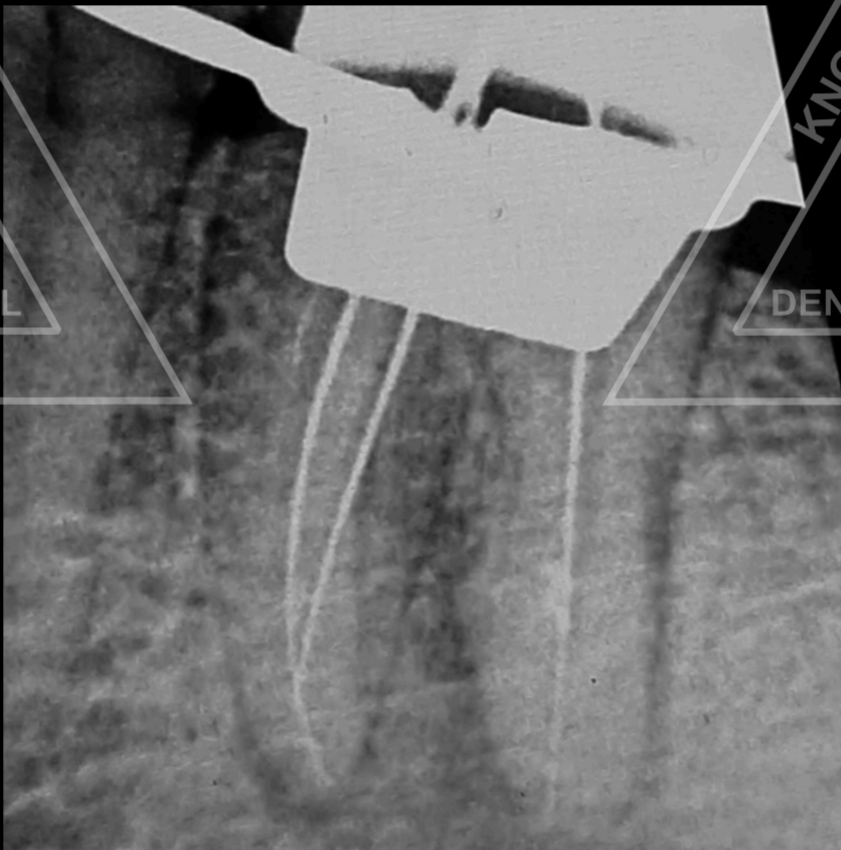
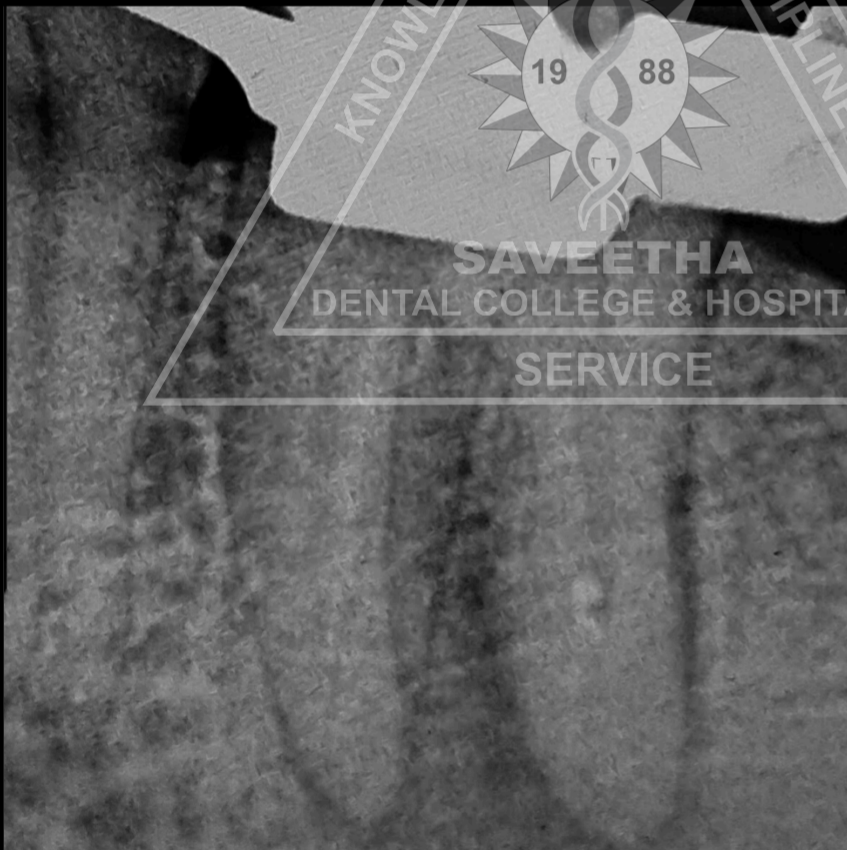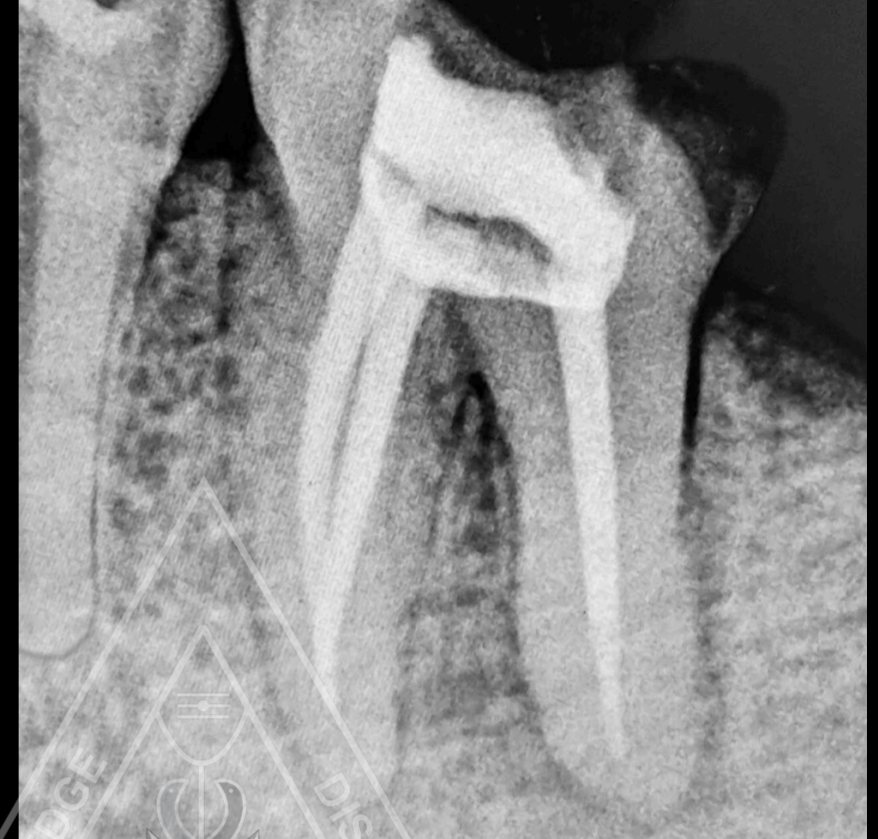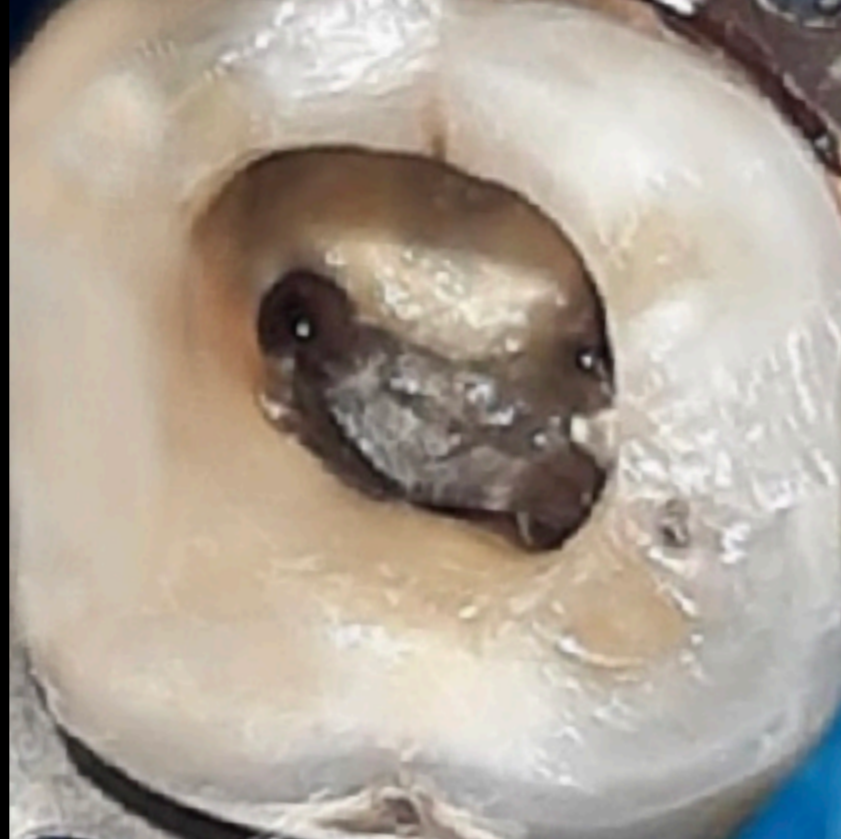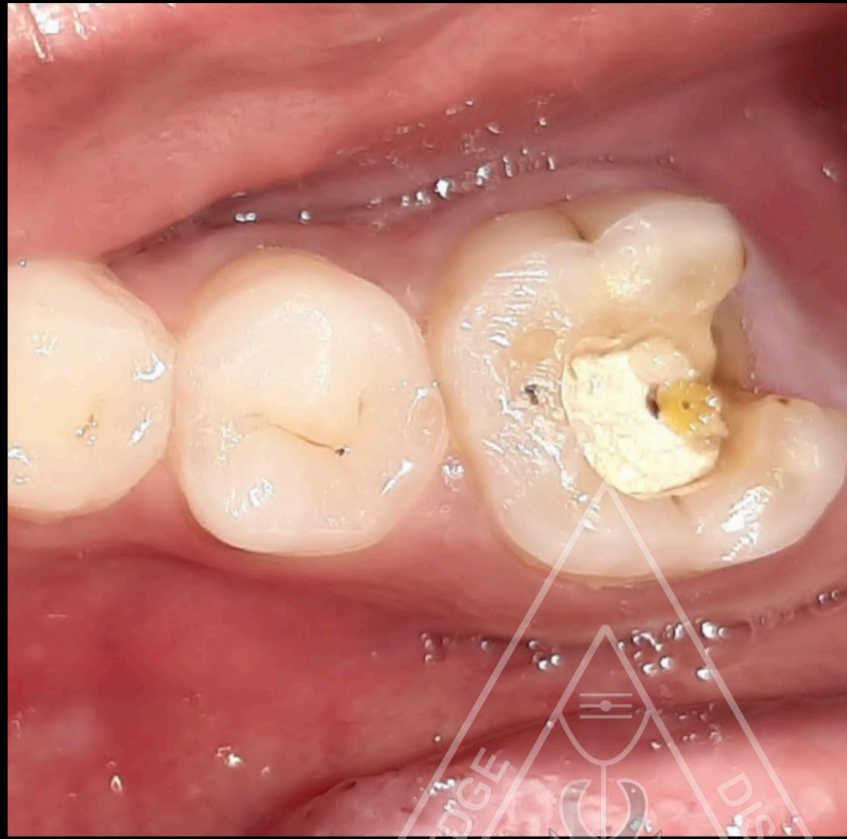
# ROOT CANAL TREATMENT IN 36



**Dr S B DIVYA**

**I MDS ENDODONTICS**

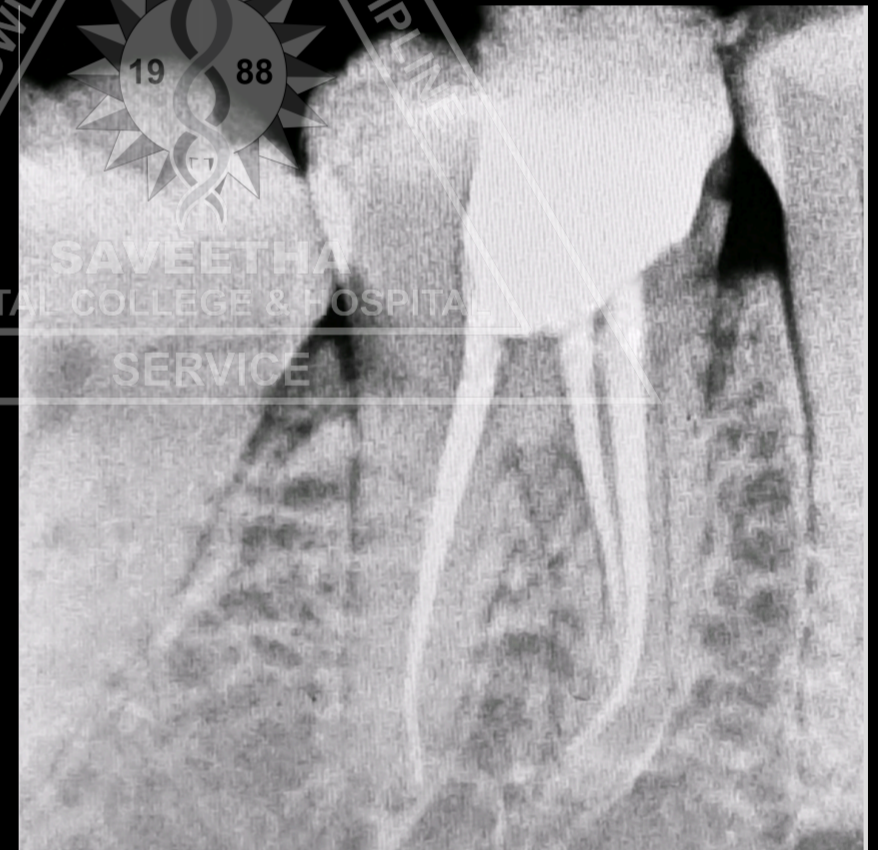
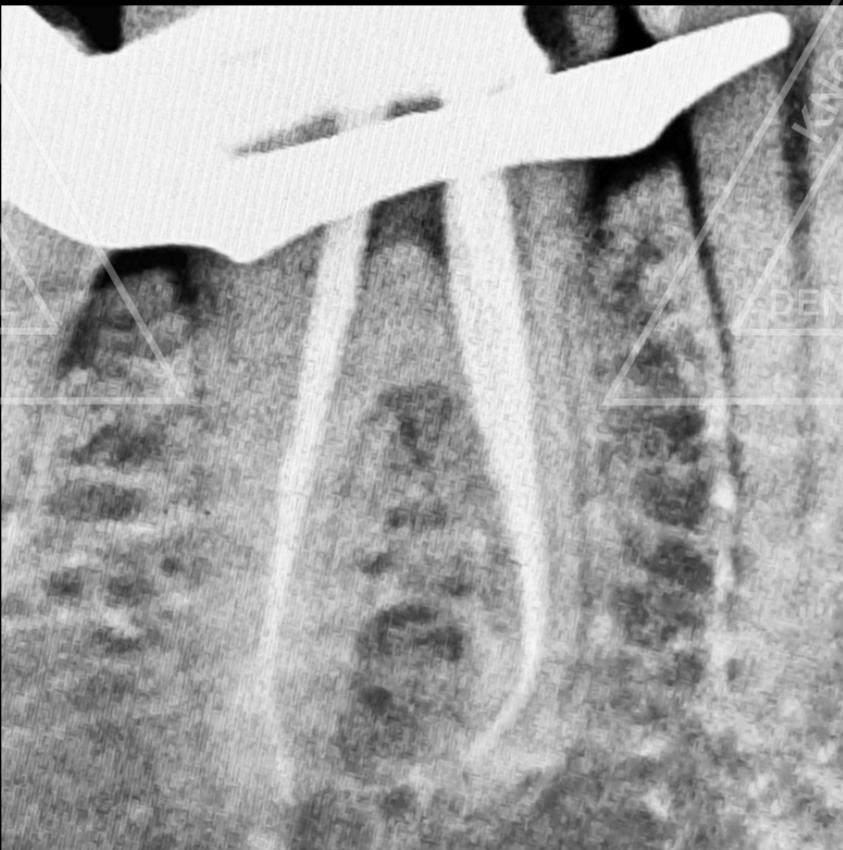
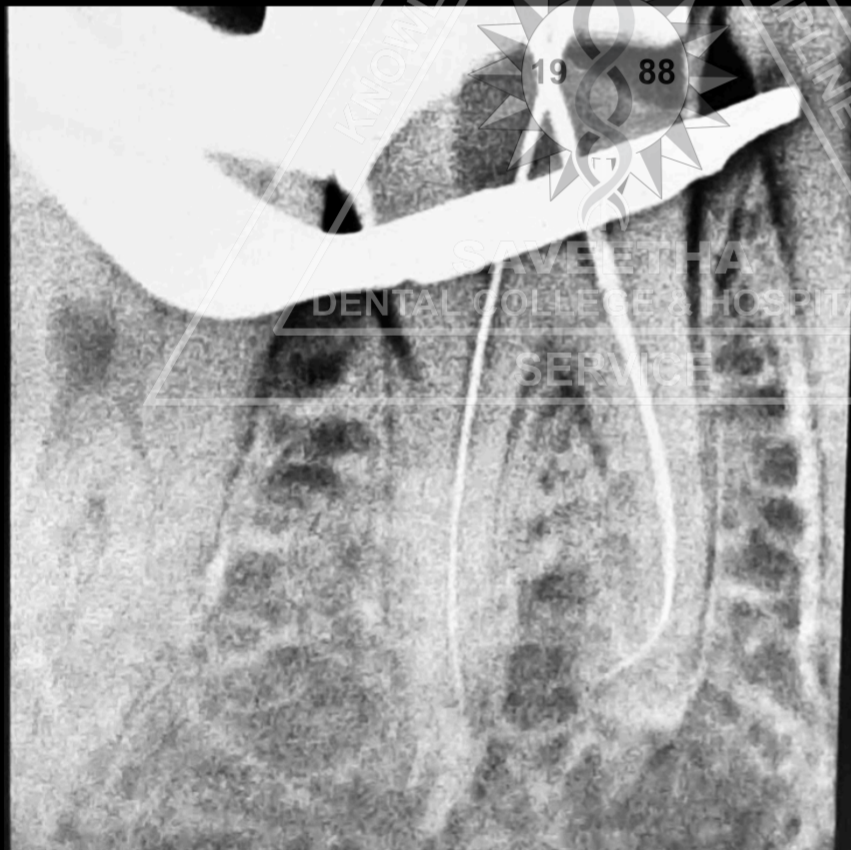
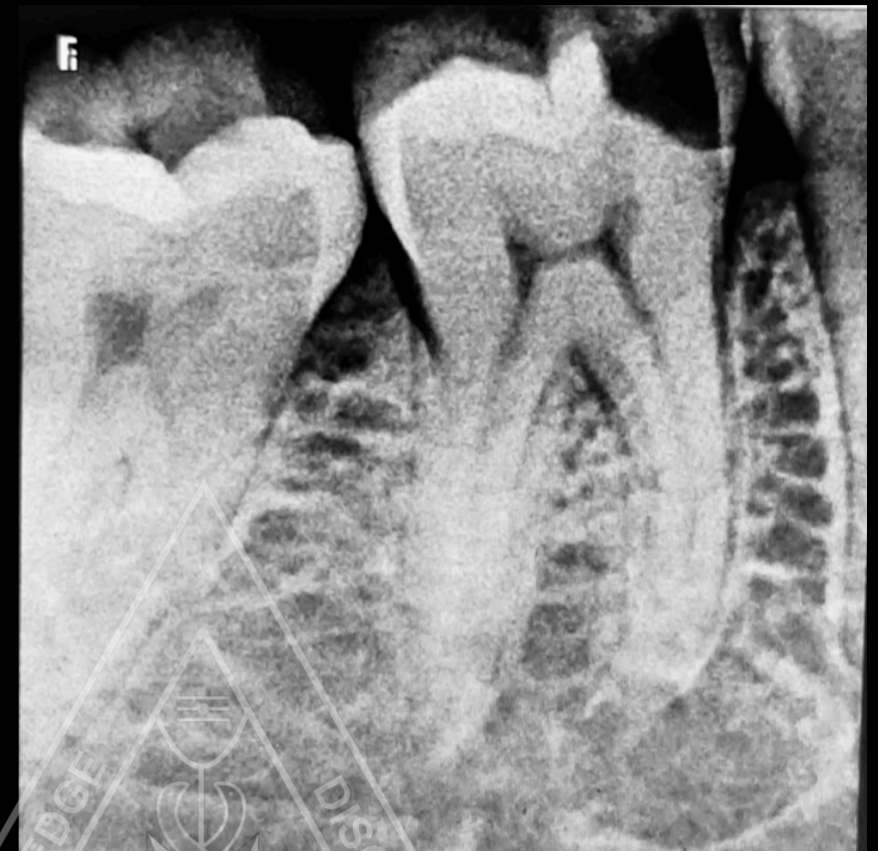
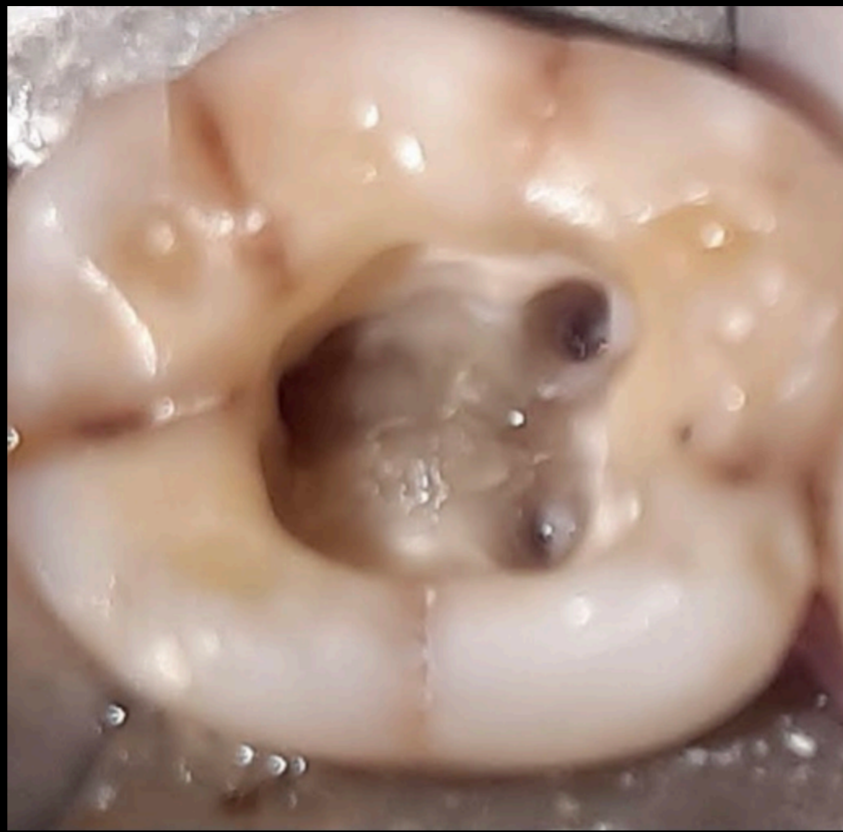
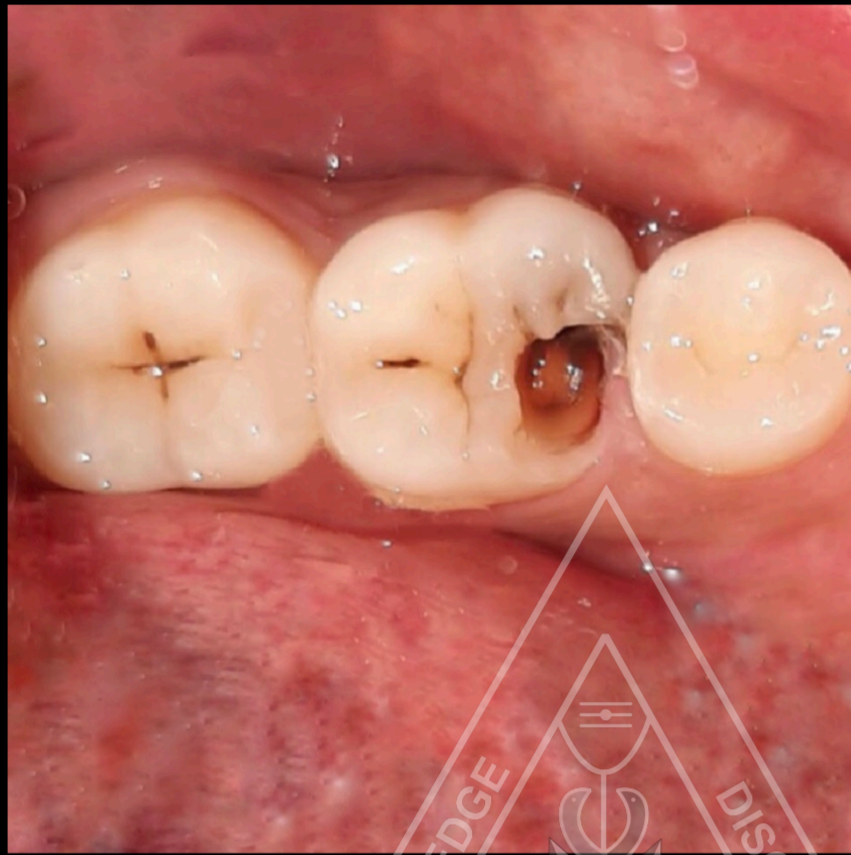
# RETREATMENT ROOT CANAL TREATMENT IN 36



**Dr S B DIVYA**

**I MDS ENDODONTICS**

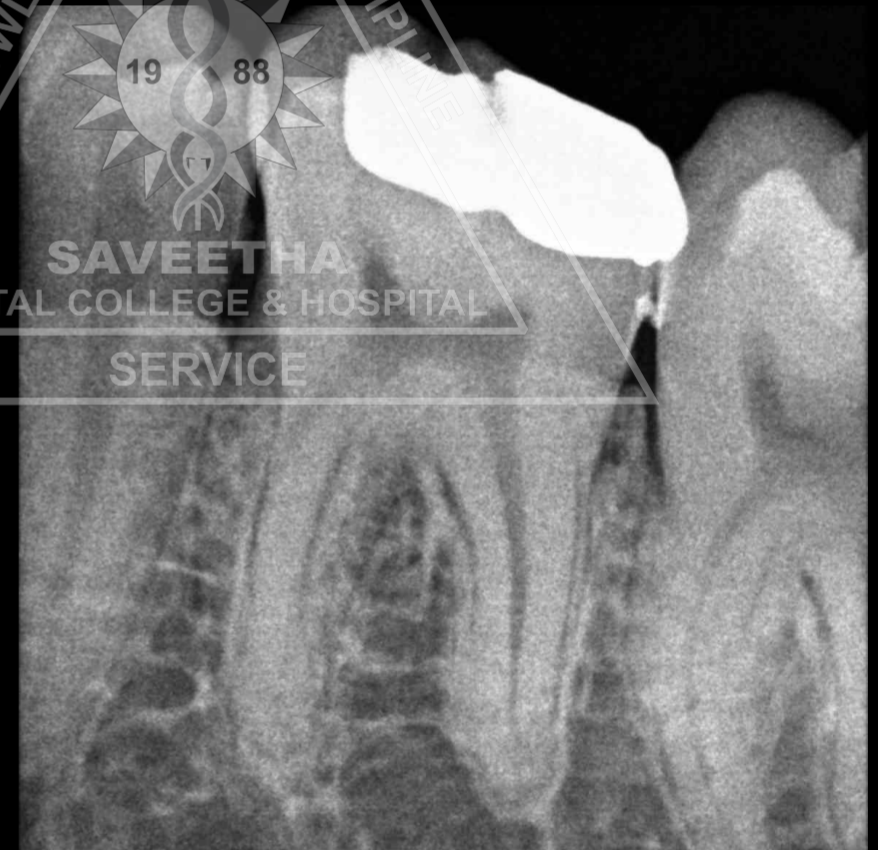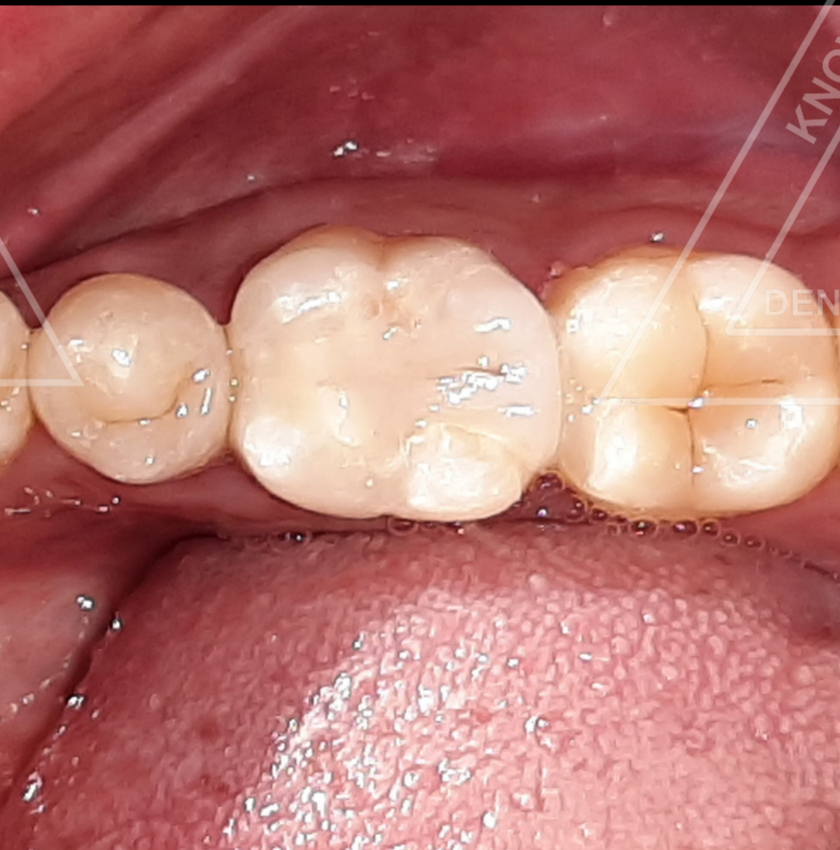
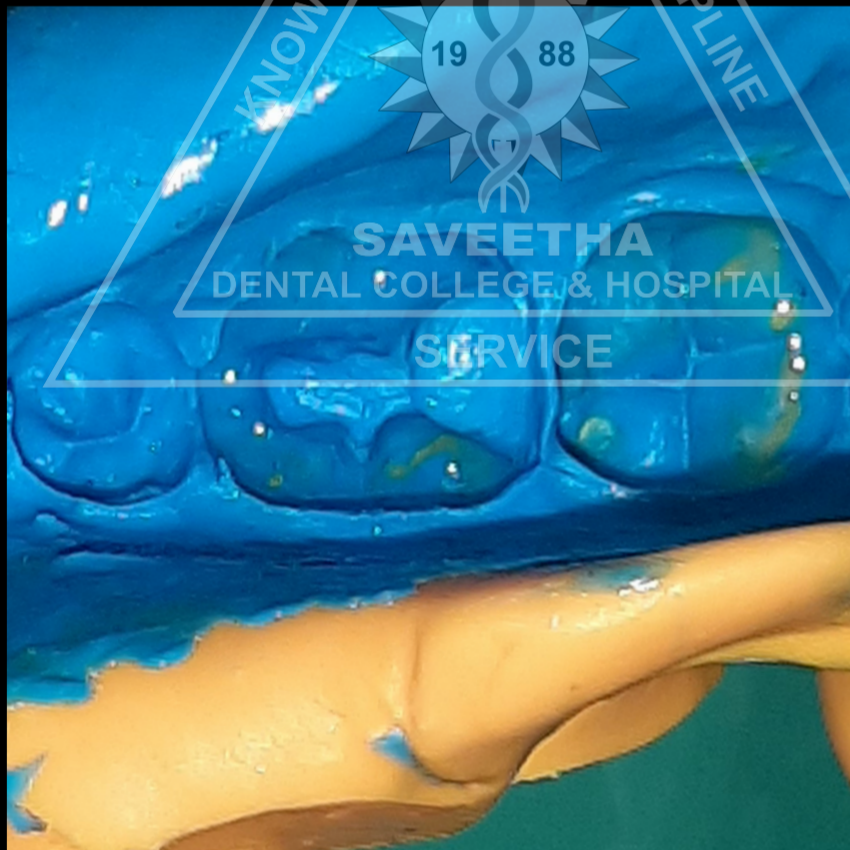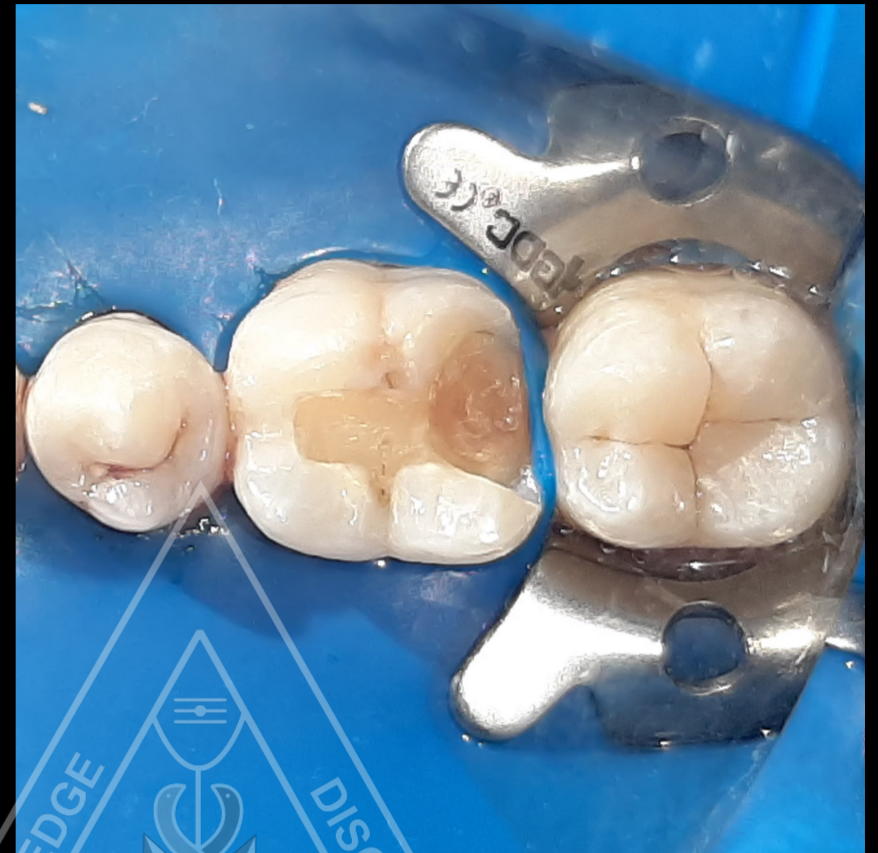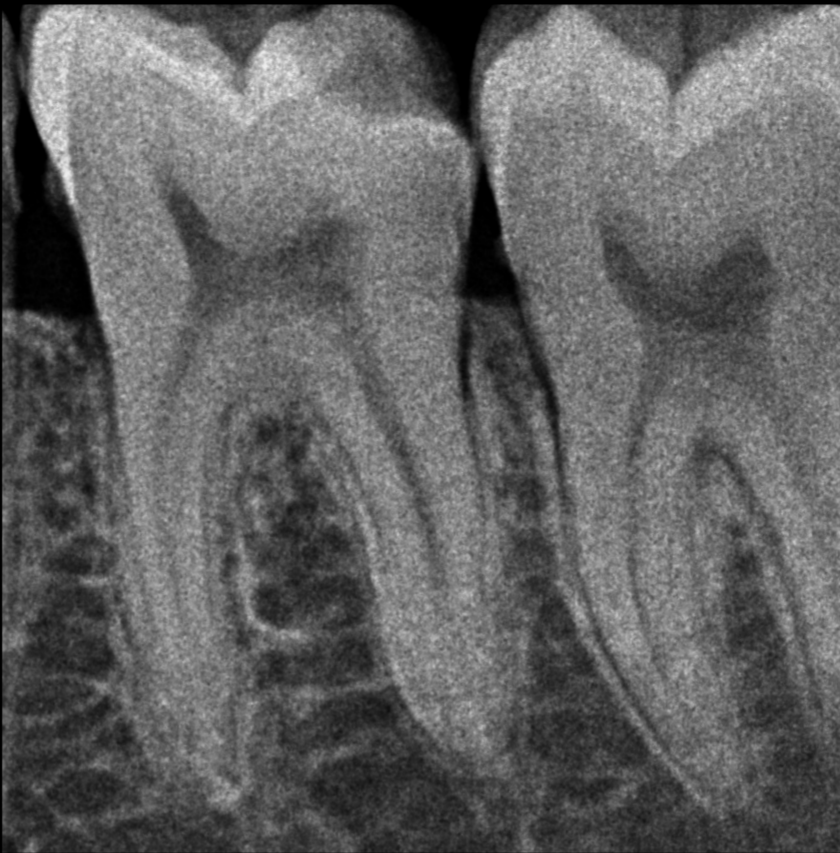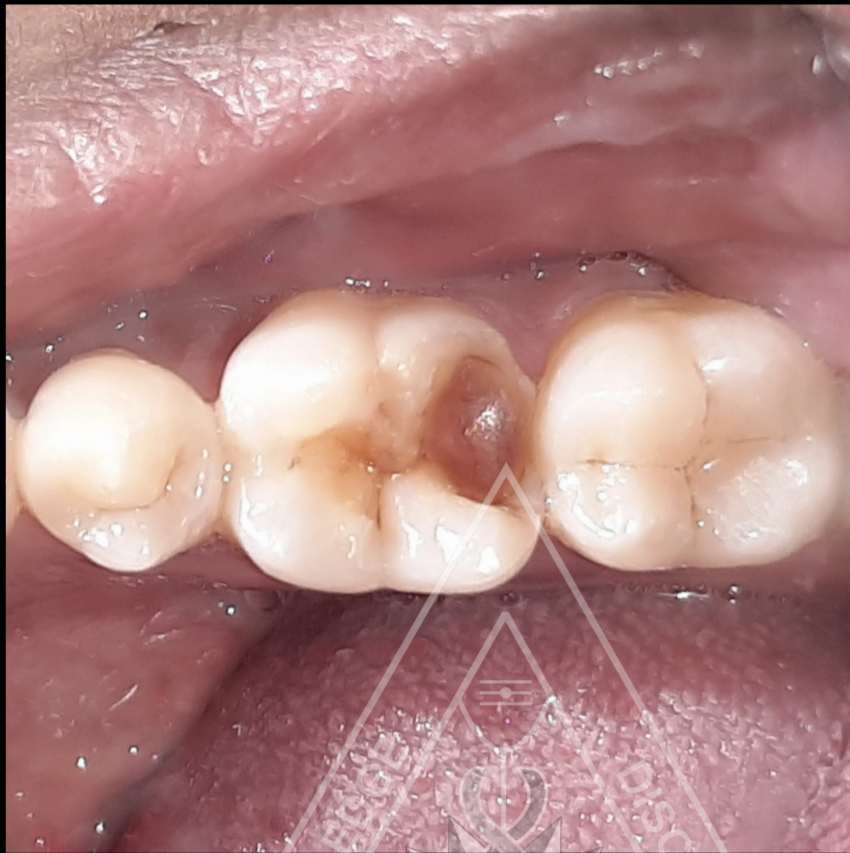# ROOT CANAL TREATMENT IN 46



**Dr S B DIVYA**

**I MDS ENDODONTICS**

# CERAMIC INLAY IN 46



**Dr S B DIVYA**

**I MDS ENDODONTICS**