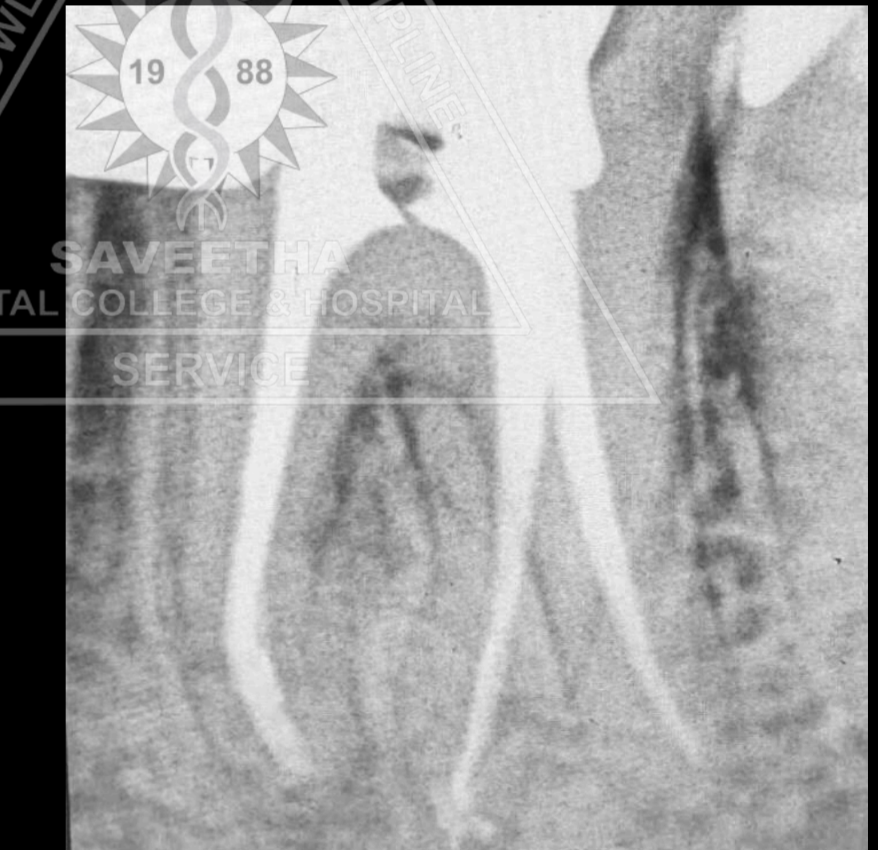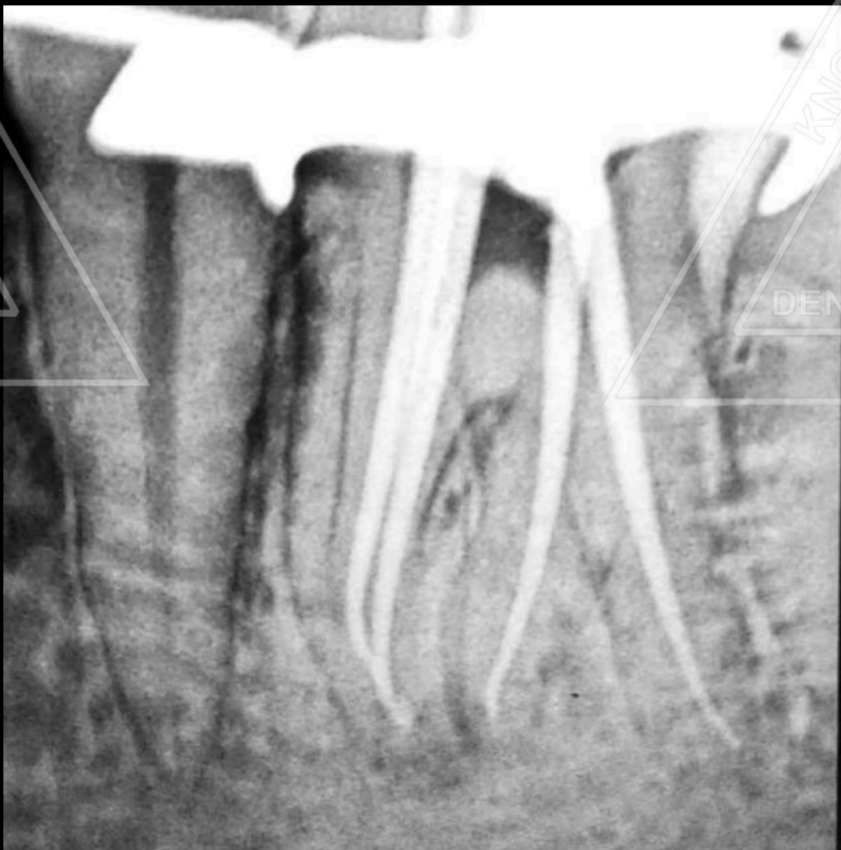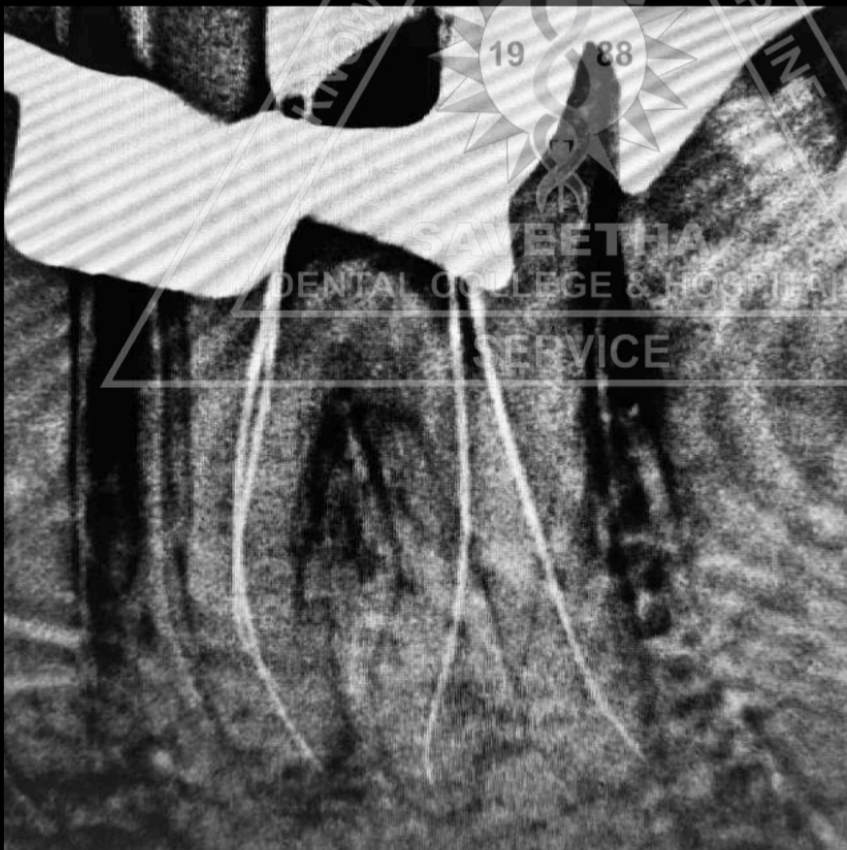


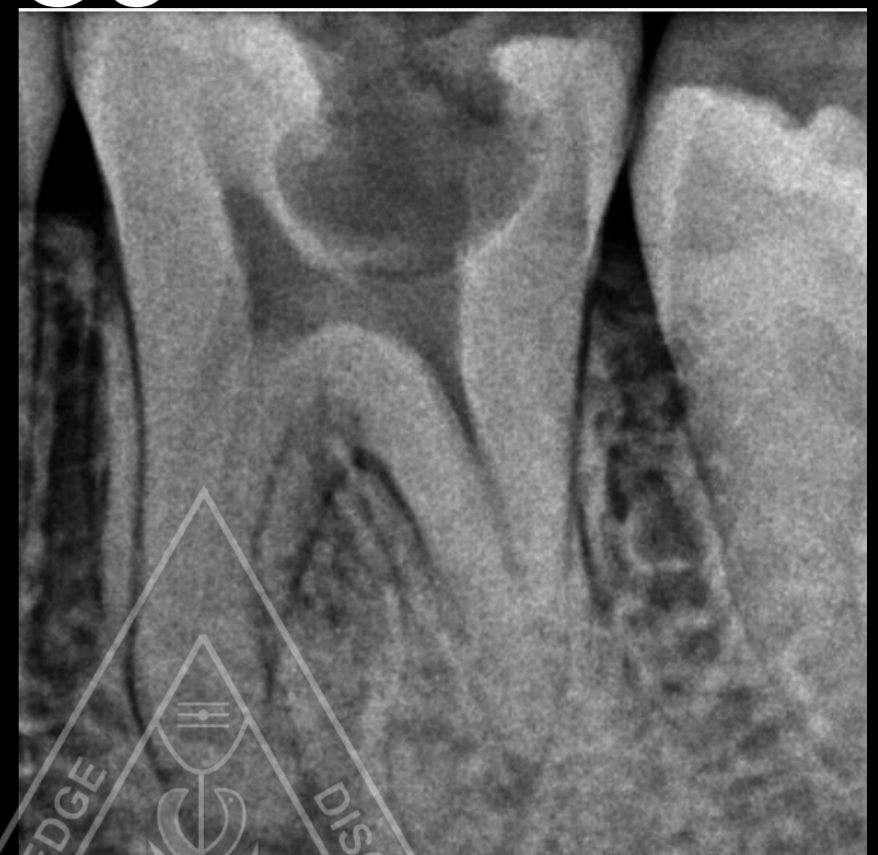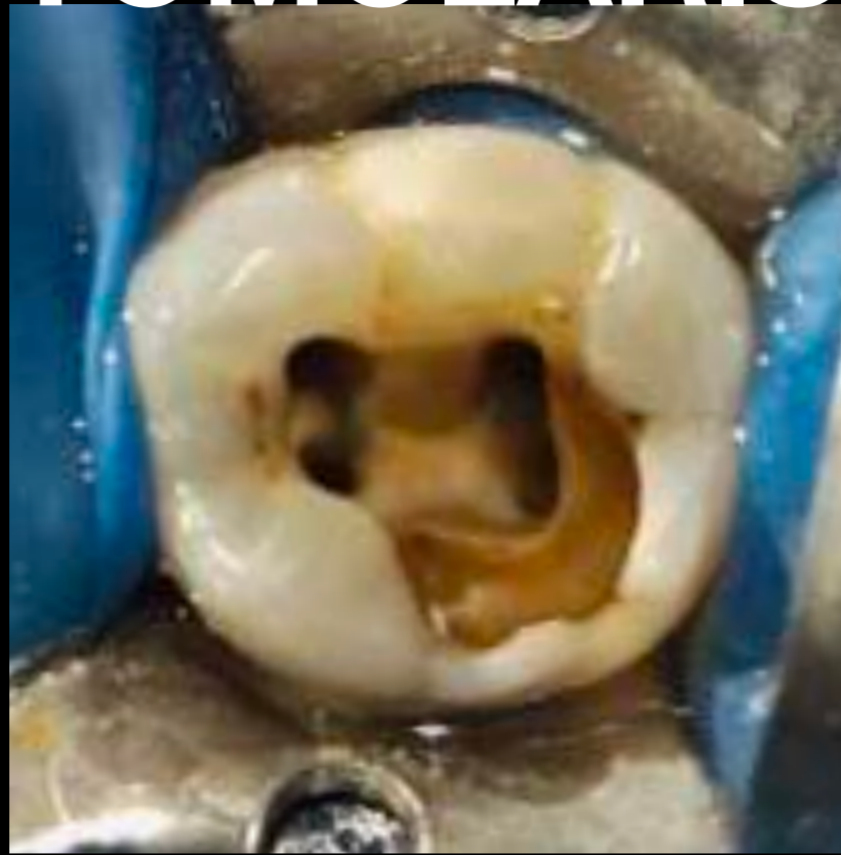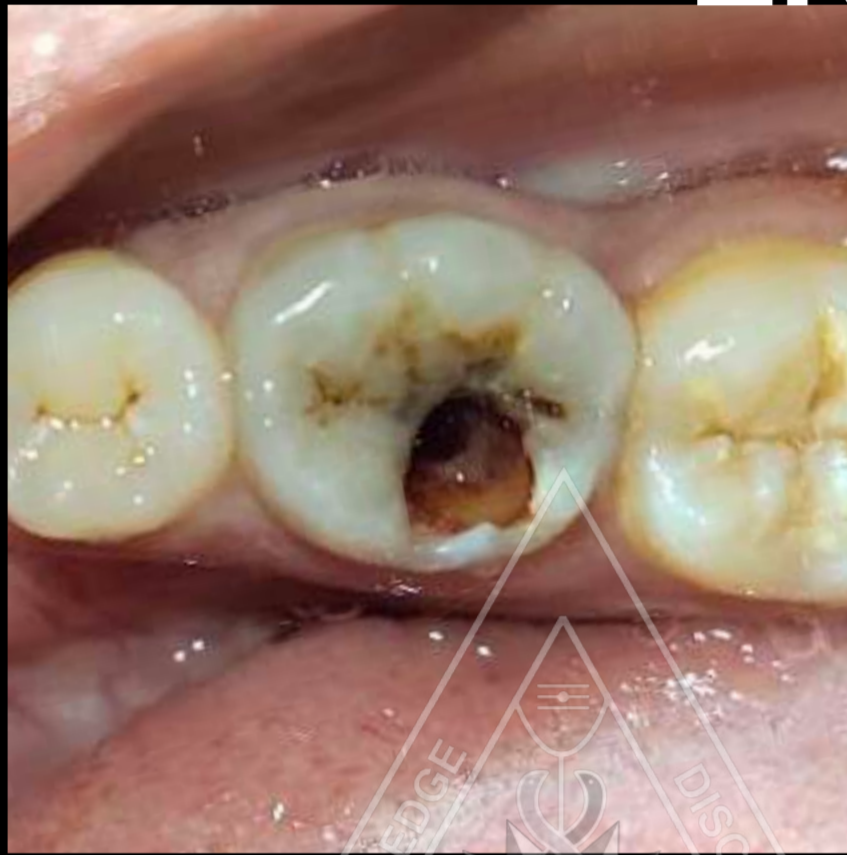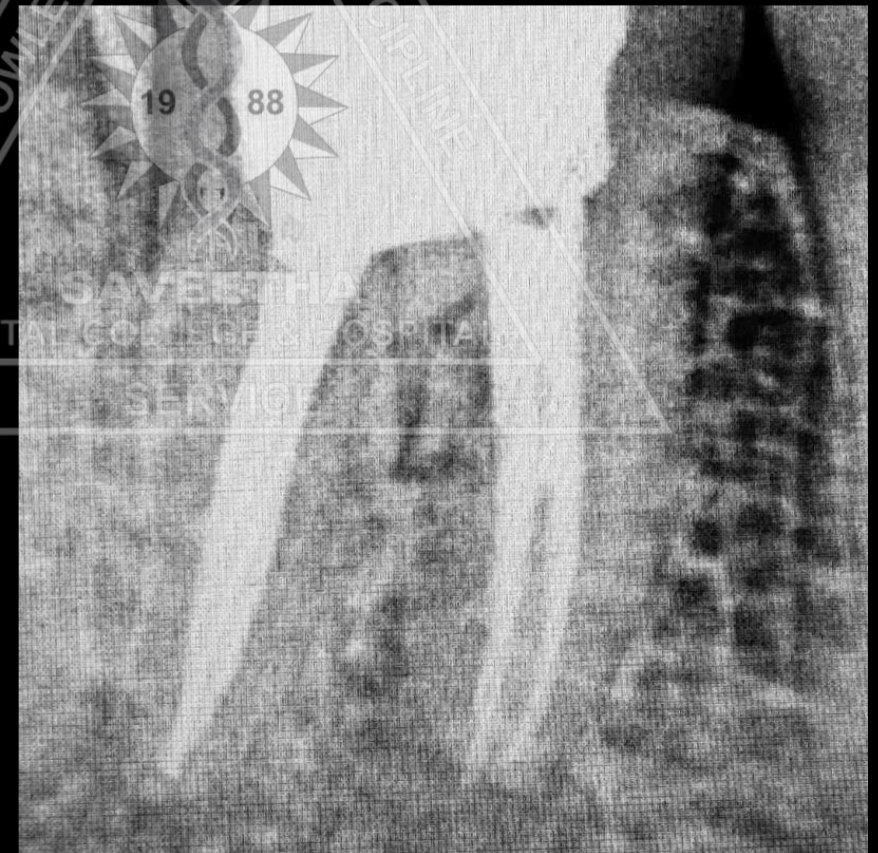
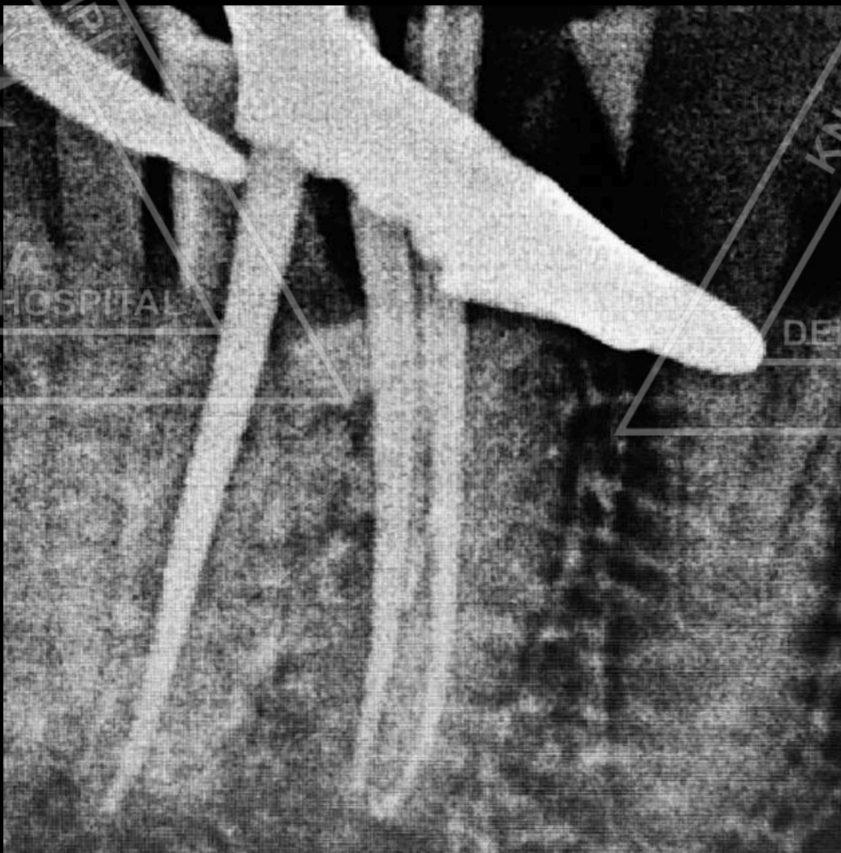
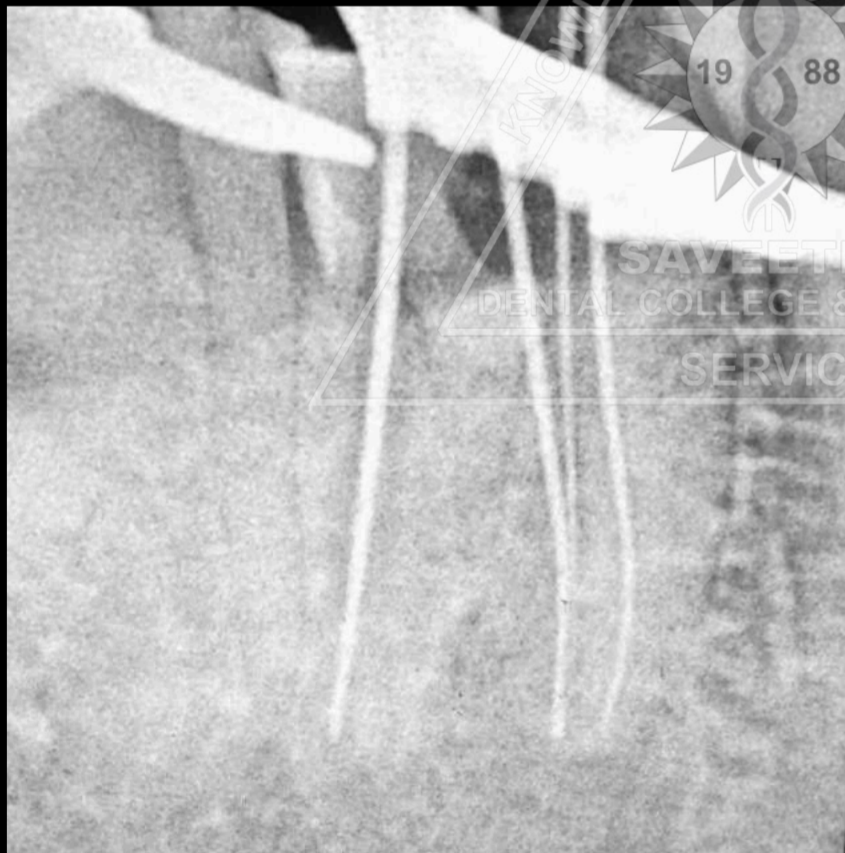
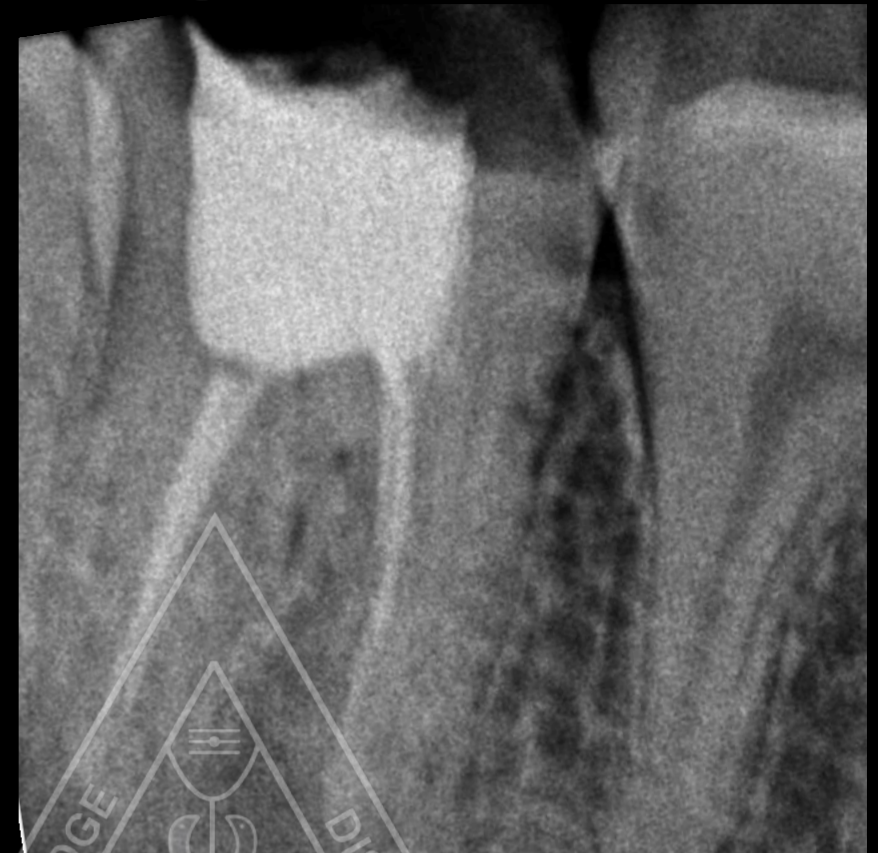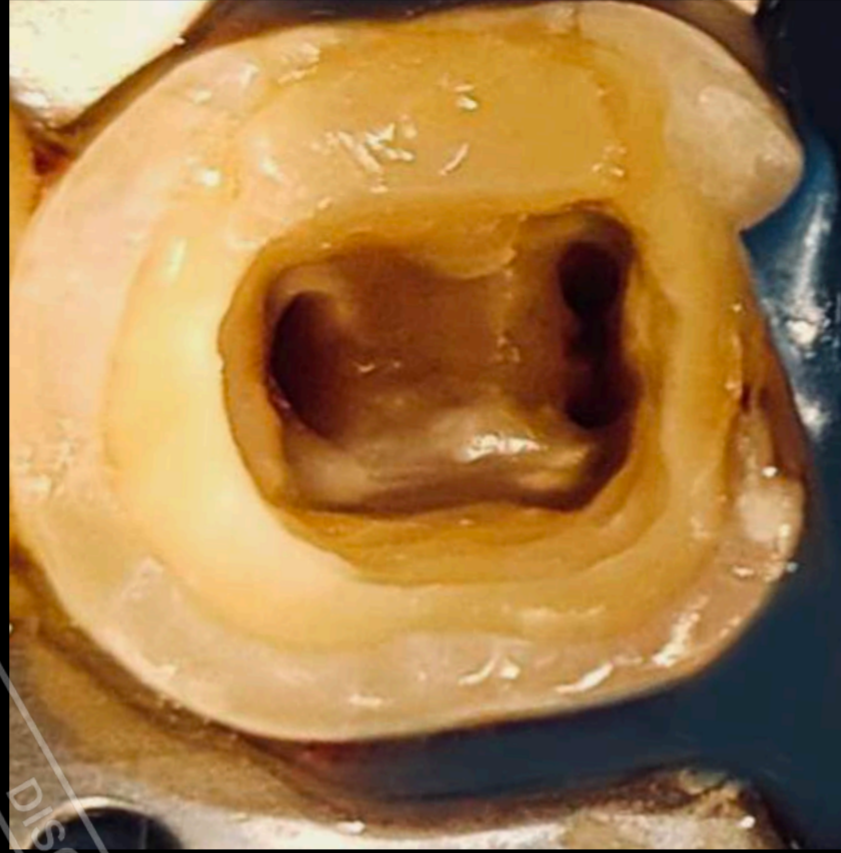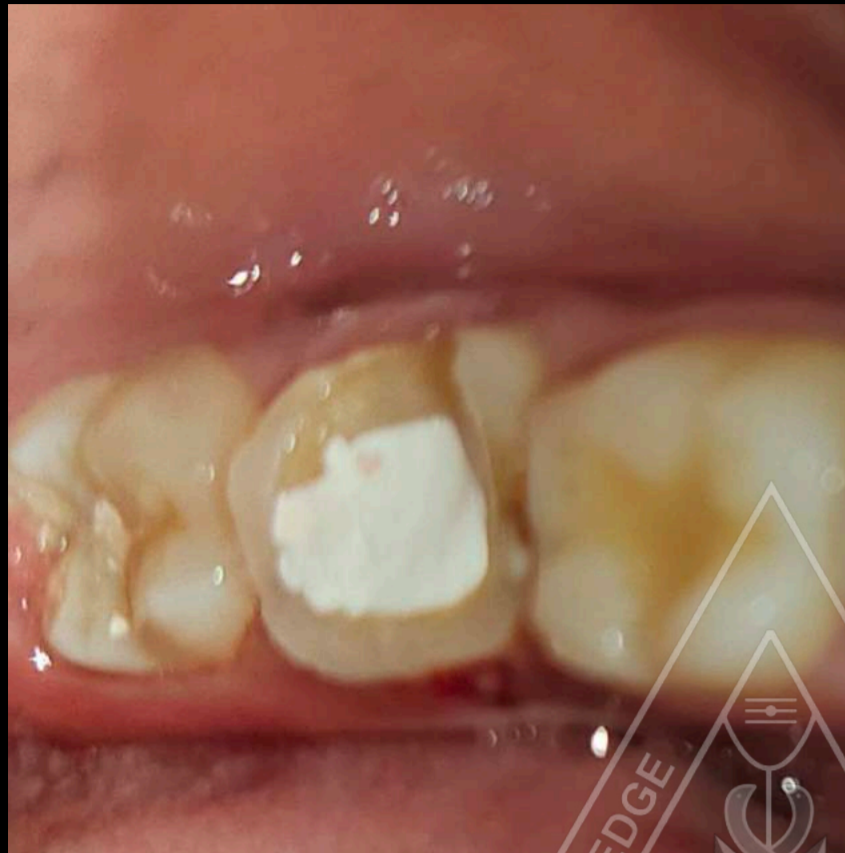# ROOT CANAL TREATMENT IN RADIX ENTOMOLARIS 36



**Dr. Nishitha Arun**  
**Dept. of Conservative Dentistry and Endodontics**

**1 yr PG**

# RE ROOT CANAL TREATMENT IN 47 WITH MIDDLE MESIAL CANAL

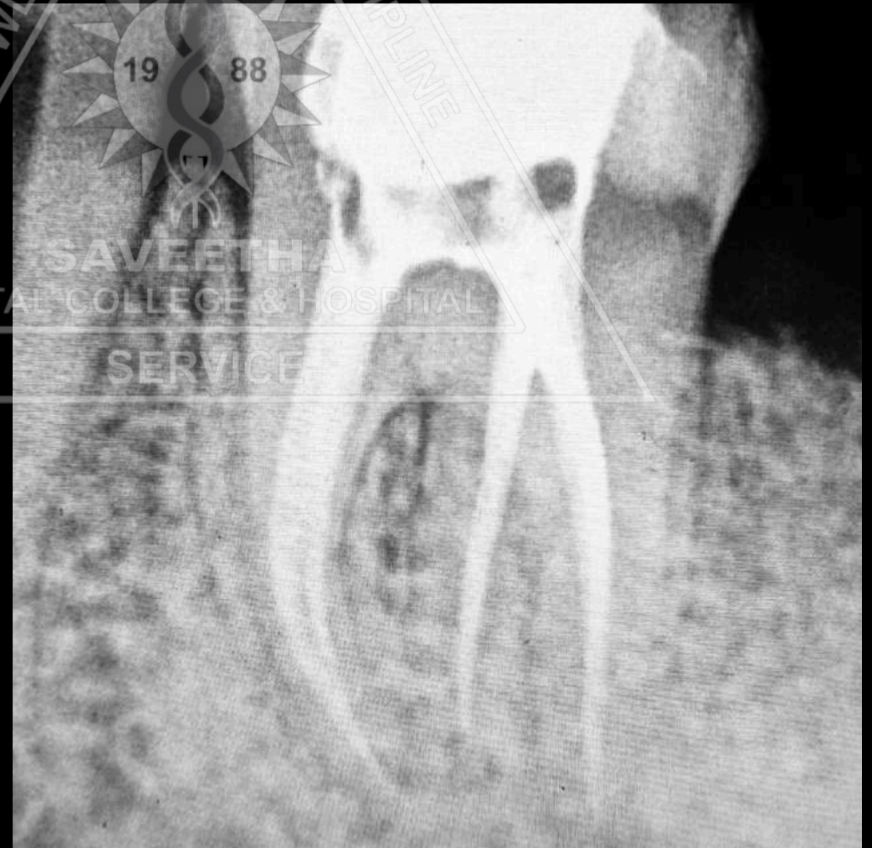
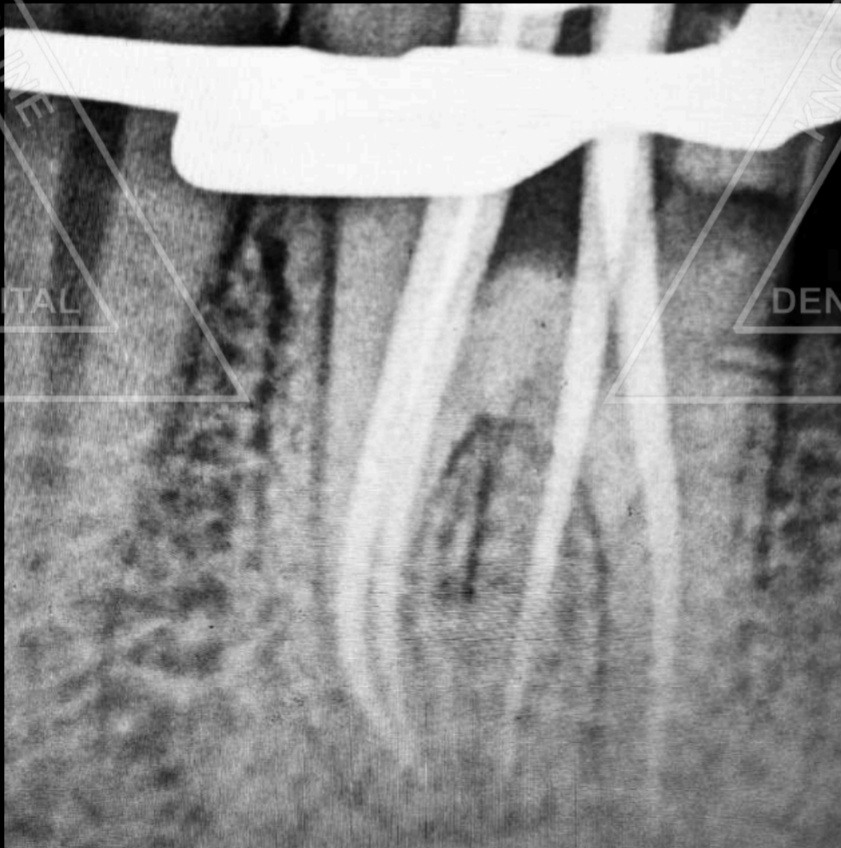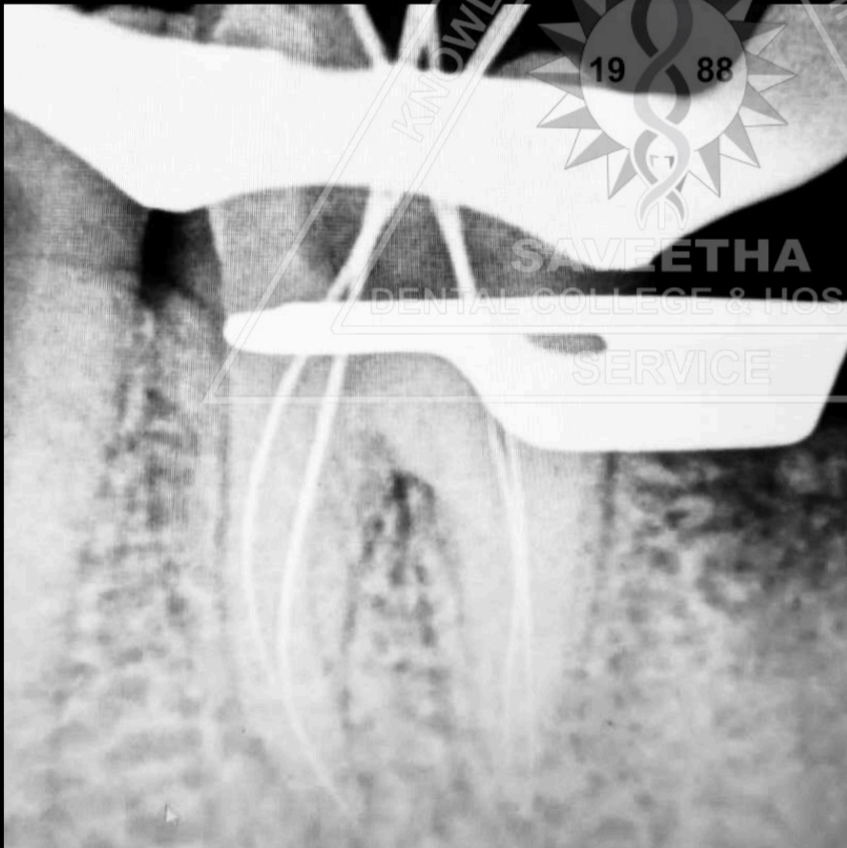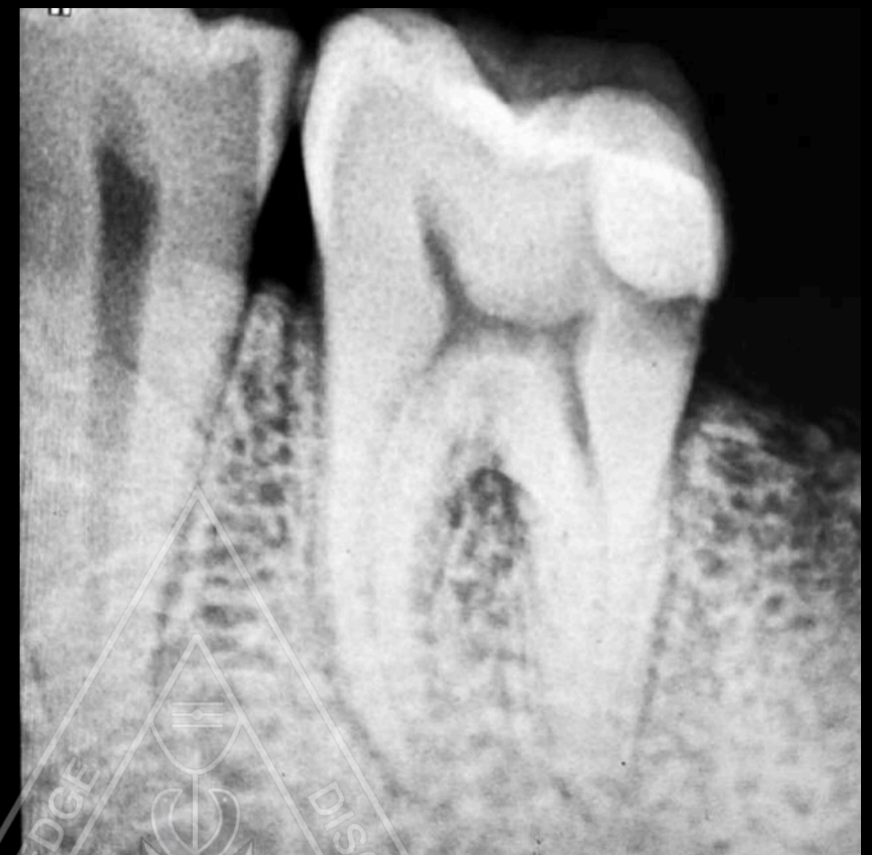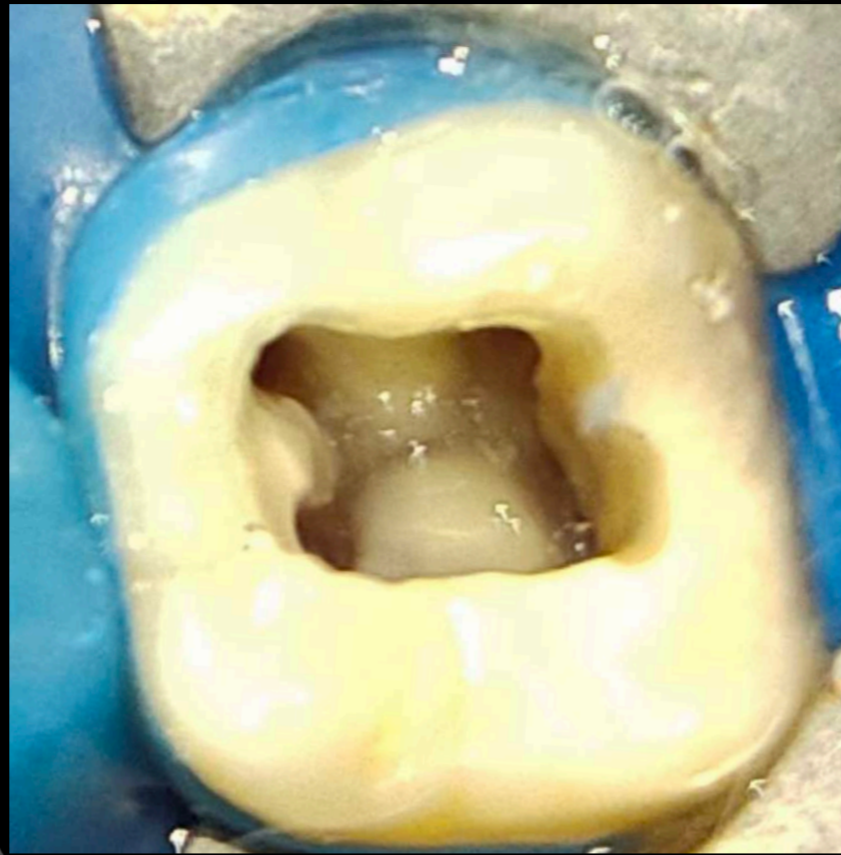
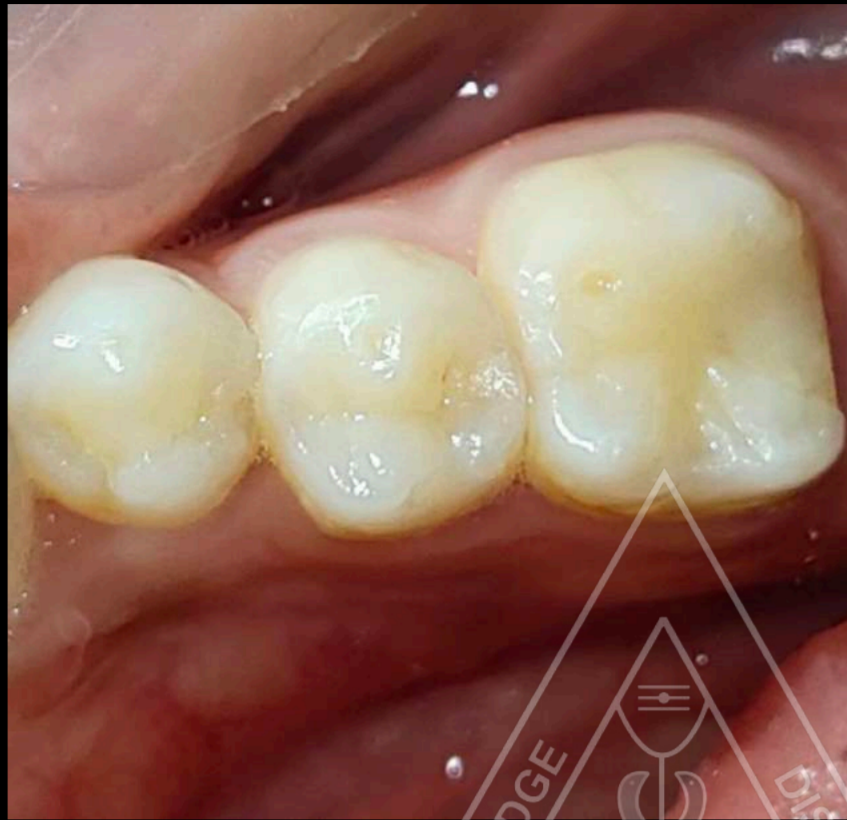


**Dr. Nishitha Arun**

**Dept. of Conservative Dentistry and Endodontics**

**I yr PG**

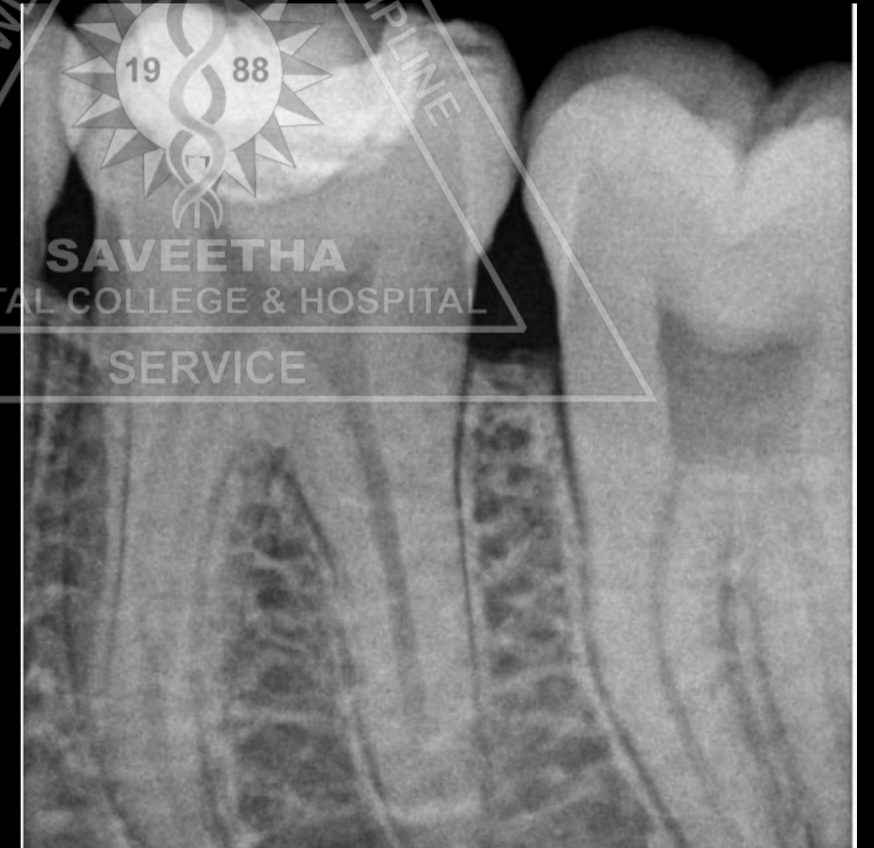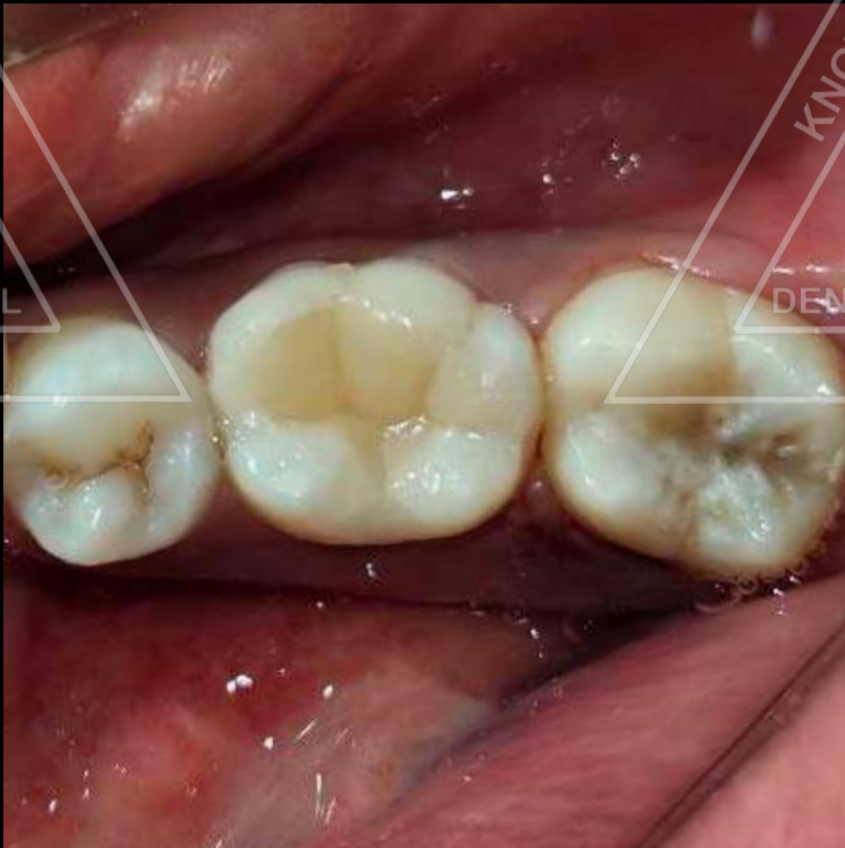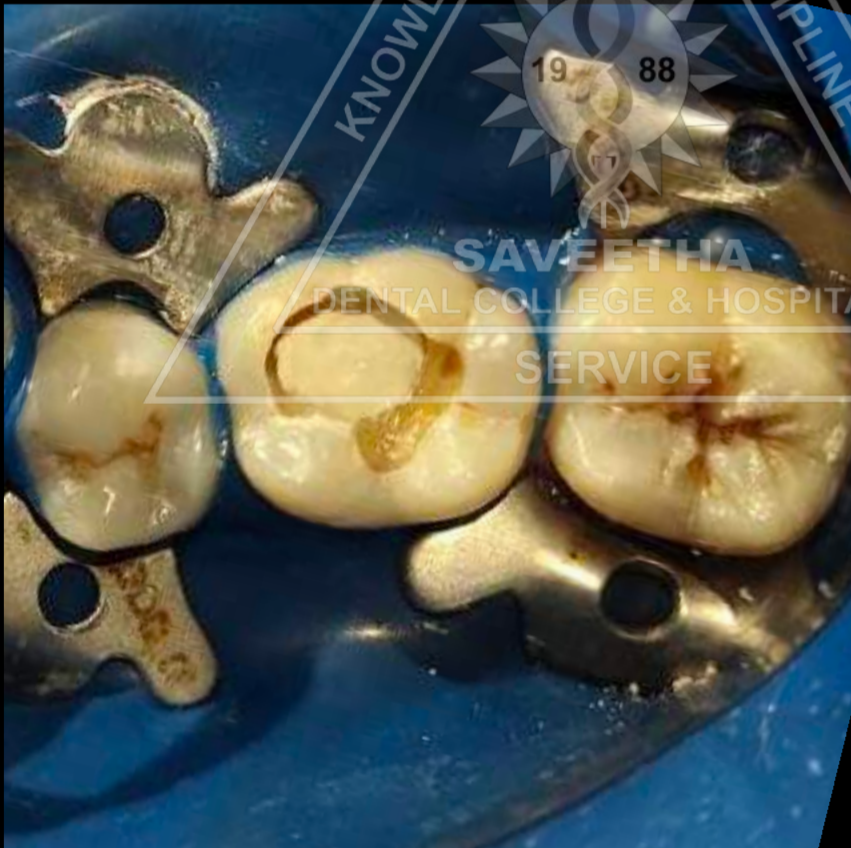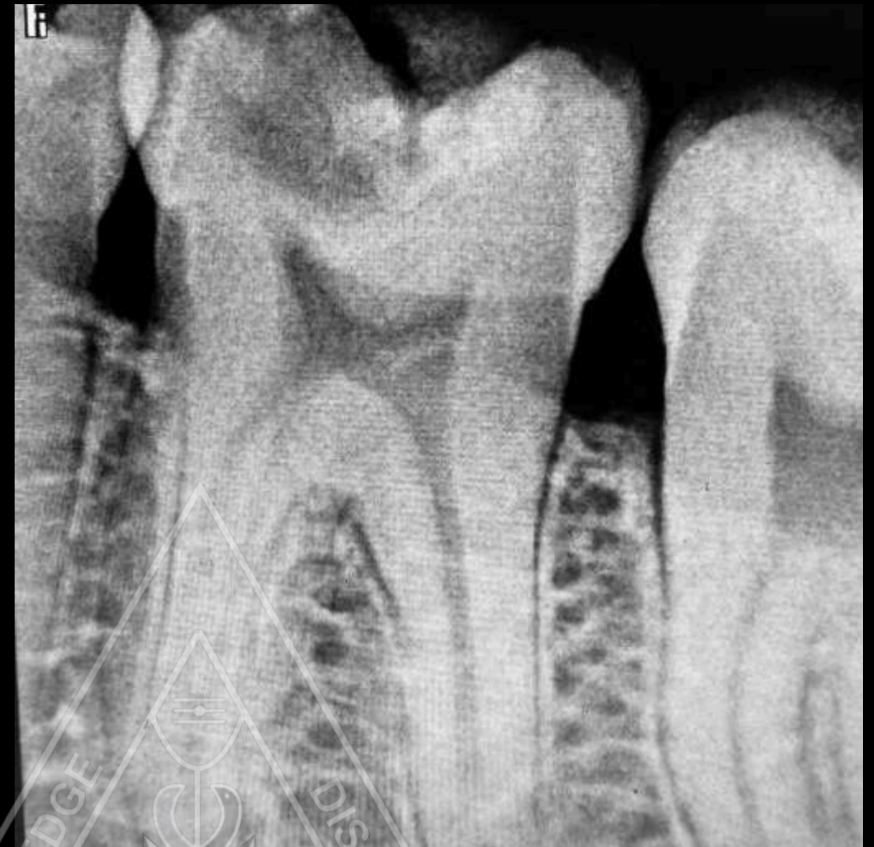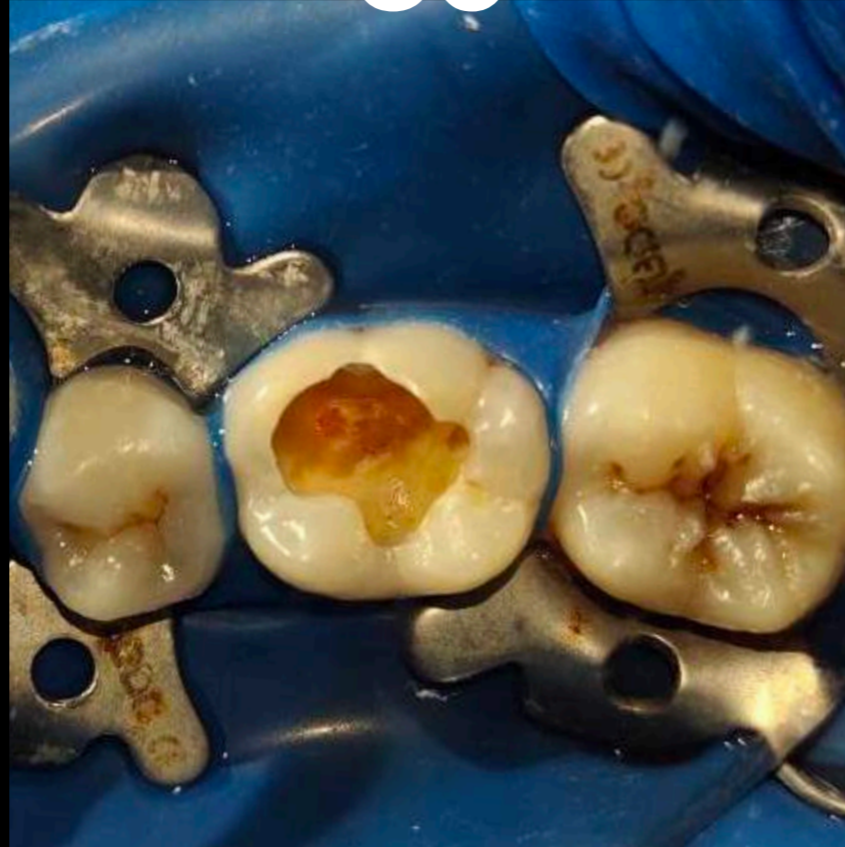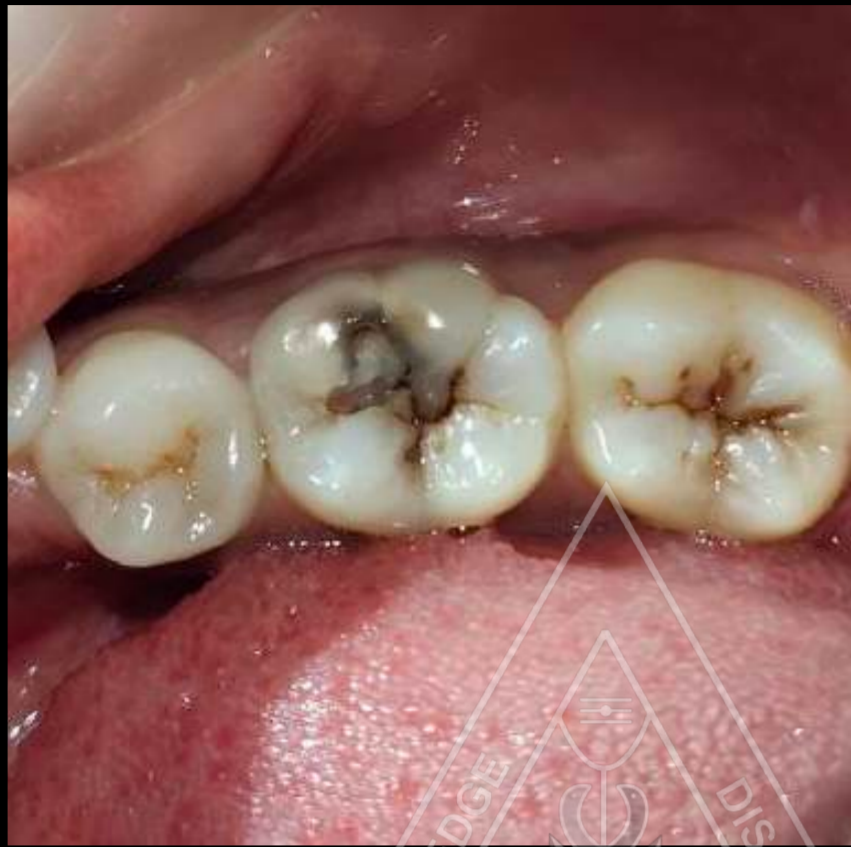# ROOT CANAL TREATMENT IN RADIX ENTOMOLARIS 36



**Dr. Nishitha Arun**  
**Dept. of Conservative Dentistry and Endodontics**  
**I yr PG**

# DIRECT PULP CAPPING WITH MTA IN

## 36

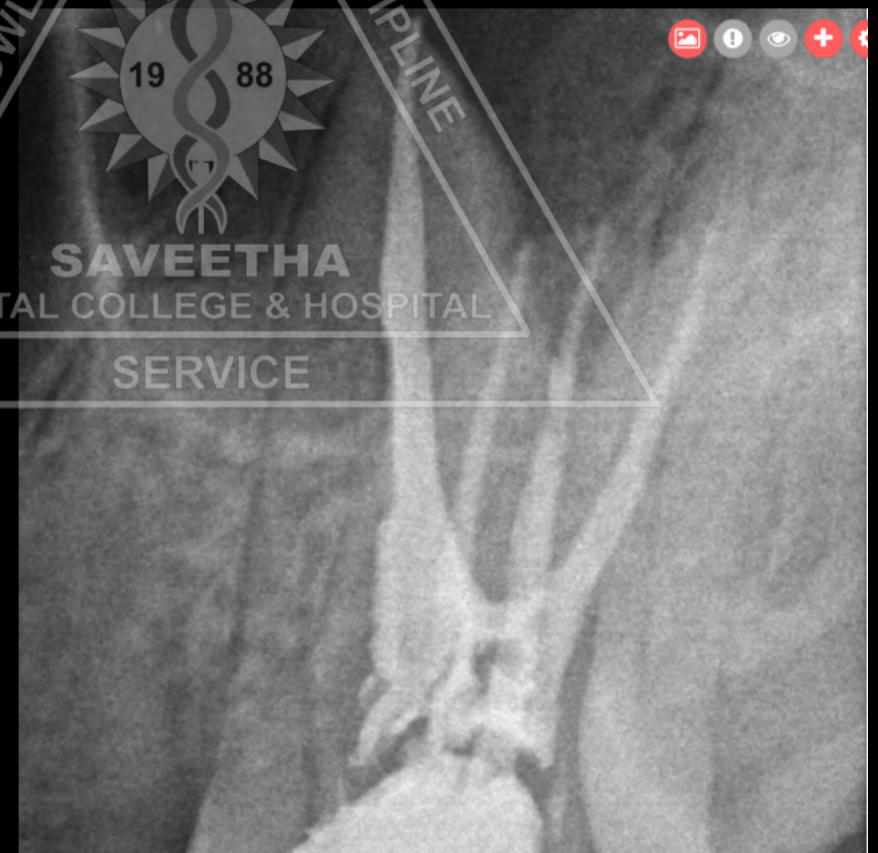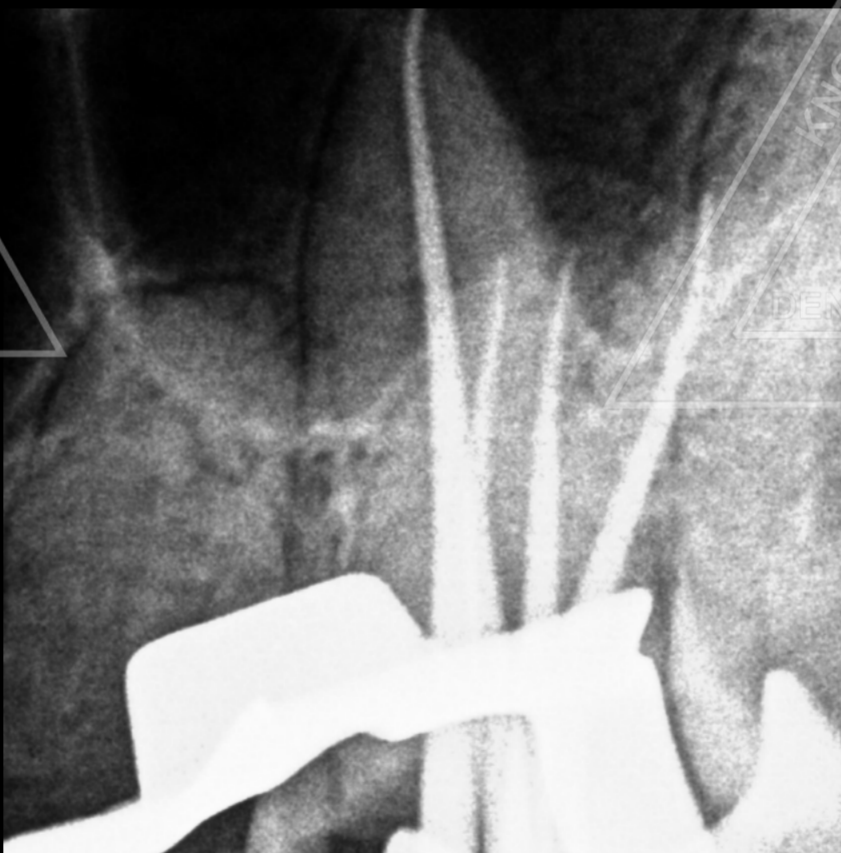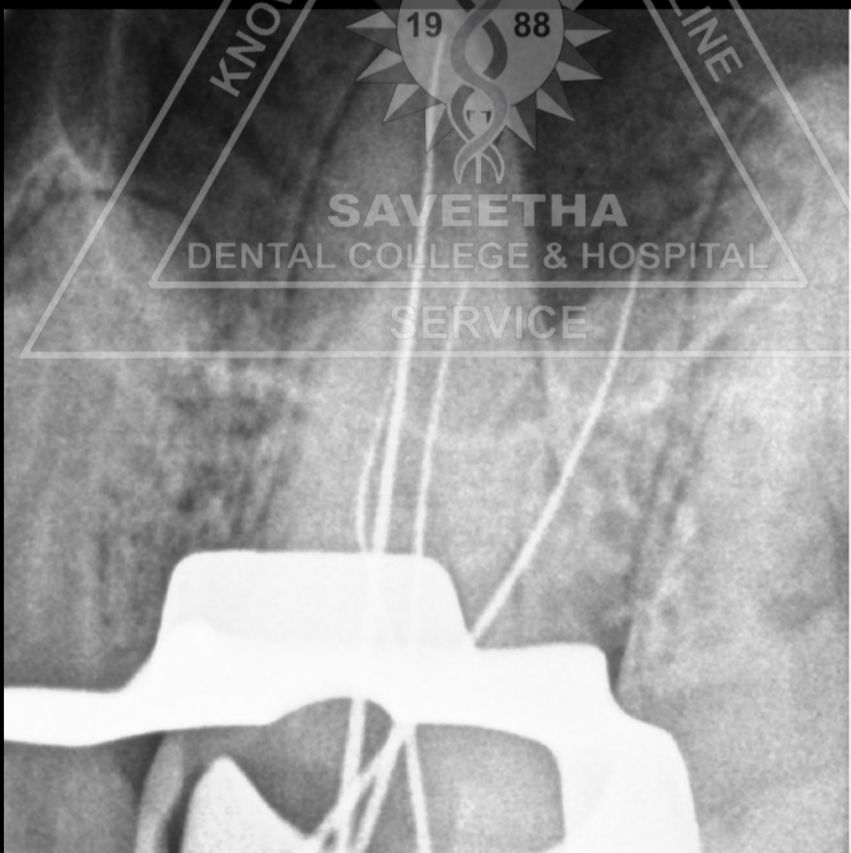
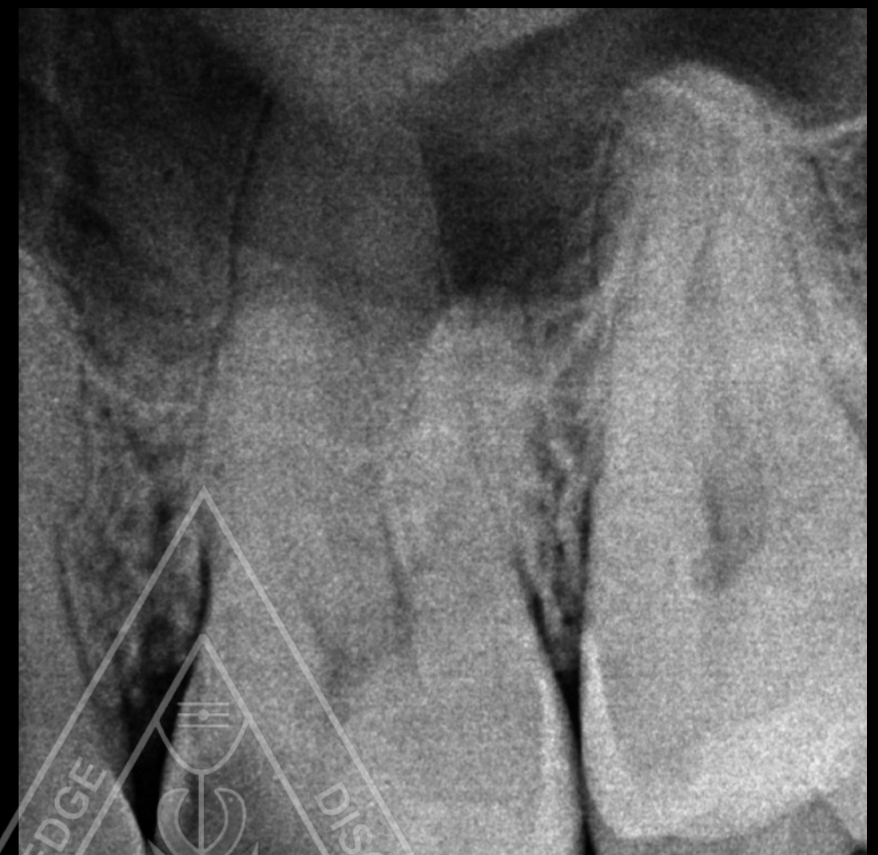


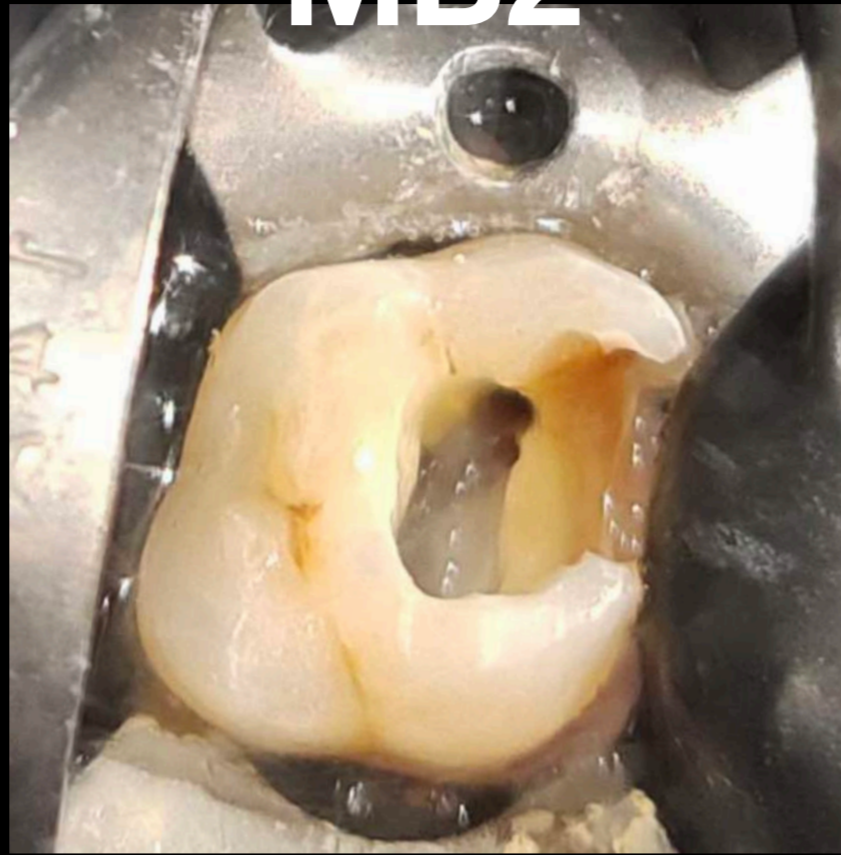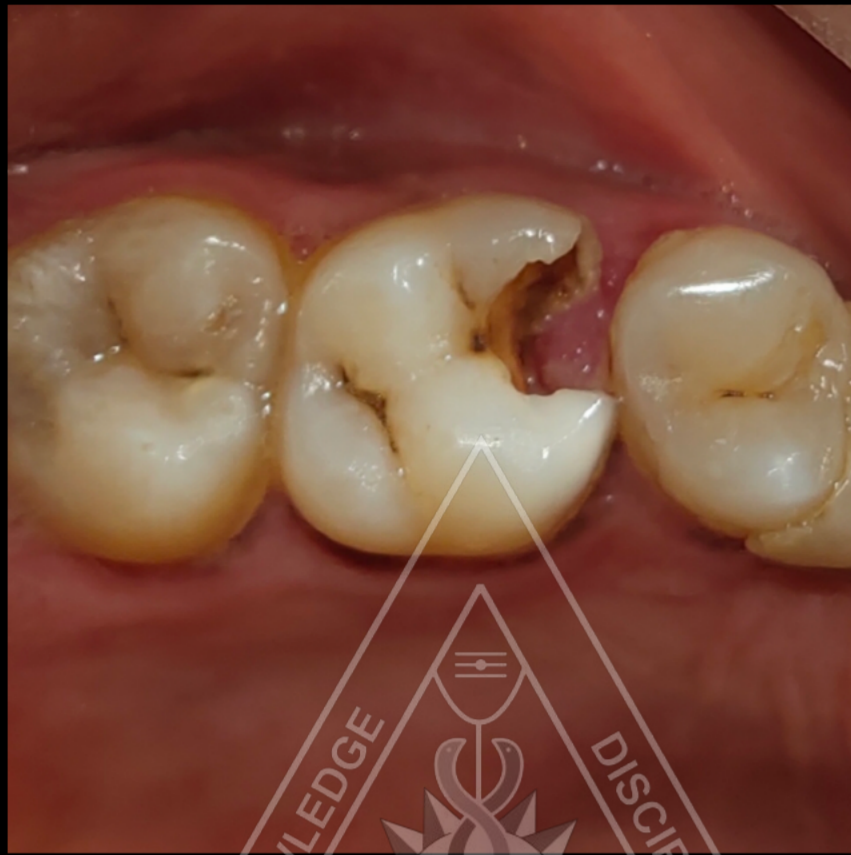**Dr. Nishitha Arun**

**Dept. of Conservative Dentistry and Endodontics**

**I yr PG**

# ROOT CANAL TREATMENT IN 26 WITH MB2



**Dr. Nishitha Arun**

**Dept. of Conservative Dentistry and Endodontics**

**I yr PG**